

Pulmonary sarcoidosis

J.P. Lynch 3rd*, E.S. White#

*Division of Pulmonary, Critical Care Medicine and Hospitalists, Dept of Internal Medicine, The David Geffen School of Medicine, University of California, Los Angeles, CA, and #Division of Pulmonary and Critical Care Medicine, Dept of Internal Medicine, University of Michigan Medical School, Ann Arbor, MI, USA.

Correspondence: J.P. Lynch 3rd, The David Geffen School of Medicine at the University of California, Division of Pulmonary, Critical Care Medicine, and Hospitalists, 10833 Le Conte Ave, 37-131 CHS, Los Angeles, CA 90095, USA. Fax: 1 3102068622; E-mail: jplynch@mednet.ucla.edu

Sarcoidosis can affect any organ system [1], but pulmonary manifestations typically dominate [2]. Abnormalities on chest radiographs are detected in 85–95% of patients [2–7]. However, 30–60% of patients with sarcoidosis are asymptomatic, with incidental findings on chest radiographs [2, 6, 8, 9]. The clinical course is heterogeneous; spontaneous remissions occur in nearly two-thirds of patients, but the course is chronic in 10–30% [3–7, 10]. Chronic, progressive pulmonary sarcoidosis may result in severe respiratory failure [11]. Fatality rates ascribed to sarcoidosis range from 2–5% [3–5, 12–14], but rates are lower (<1%) in nonreferral settings [6–9]. In the USA, 87% of deaths attributed to sarcoidosis were secondary to pulmonary complications [15]. In contrast, in Japan, 77% of deaths resulted from cardiac involvement.

Clinical features of pulmonary sarcoidosis

Nonproductive cough, dyspnoea and chest pain are the most common features of pulmonary sarcoidosis, occurring in 30–50% of patients [16]. These features may be more prominent in patients with significant endobronchial or pulmonary parenchymal involvement [2, 17]. In contrast to idiopathic pulmonary fibrosis (IPF), physical findings are usually minimal or absent in pulmonary sarcoidosis. Crackles are present in <20% of patients with sarcoidosis, even when radiographic infiltrates are extensive [2]. Clubbing, which is observed in 25–50% of patients with IPF [18], is rarely observed in sarcoidosis [2]. Fatigue [19] and impaired quality of life (QoL) [20] are far more common among patients with sarcoidosis compared with healthy controls. In one study, the extent of fatigue correlated inversely with the carbon monoxide diffusing capacity of the lung (DL_{CO}), but not with forced expiratory volume in one second (FEV₁), forced vital capacity (FVC), radiographic stage or serological parameters [19].

Chest radiographic features in sarcoidosis

Chest radiographs are abnormal in >85% of patients with sarcoidosis [2–7]. The most characteristic finding (present in 50–85% of cases) is bilateral hilar lymphadenopathy (BHL), often with concomitant enlargement of the right paratracheal lymph nodes [2]. Lymph node involvement at other intrathoracic sites is often present by computed tomography (CT) scans [21, 22]. Unilateral hilar lymphadenopathy on CT is uncommon,

occurring in <10% of cases [23]. Pulmonary parenchymal infiltrates (with or without BHL) are present in 25–50% of patients with sarcoidosis, and preferentially involve the central (rather than peripheral) regions and upper lobes [2, 6]. Large bullae [24, 25], cystic bronchiectasis, or enlarged pulmonary arteries (attributable to secondary pulmonary arterial hypertension (PAH)) may complicate advanced stage III or IV sarcoidosis [26]. Rare features (occurring in 1–3% of patients) include pleural effusions [27], unilateral segmental infiltrates or mass lesions, unilateral hilar adenopathy, large nodular opacities simulating metastases [28, 29], cavitation [30, 31], and diffuse ground-glass opacities [2, 32]. The radiographic features of sarcoidosis are discussed in detail in chapter 18 of this monograph, and will not be reiterated here.

Radiographic classification schema

The radiographic staging system for pulmonary sarcoidosis was developed more than four decades ago [5]. This classification schema defines the following stages: stage 0 (normal); stage I (BHL without pulmonary infiltrates; fig. 1); stage II (BHL plus pulmonary infiltrates; fig. 2); stage III (parenchymal infiltrates without BHL; fig. 3). Stage IV (not universally adopted) refers to extensive fibrosis with distortion or bullae [6, 33] (table 1).

Although individual exceptions exist, the prognosis is best with stage I, intermediate with stage II, and worst with stage III or IV. Spontaneous remissions occur in 60–90% of patients with stage I disease, 40–70% with stage II, 10–20% with stage III, and 0% with stage IV [3–6, 14, 34, 35].

The long-term prognosis is often dictated by the evolution of the disease within the first 2–3 yrs. Several series cited improvement or stability in chest radiographs in >70% of sarcoidosis patients within 2–3 yrs of follow-up. Furthermore, several studies noted that spontaneous remission predicted a low rate (<10%) of late relapse [35–37].

In a study from New South Wales (Australia), chest radiographs normalised in 112 out of 150 (75%) patients presenting with stage I or II sarcoidosis [38]. In a cohort of

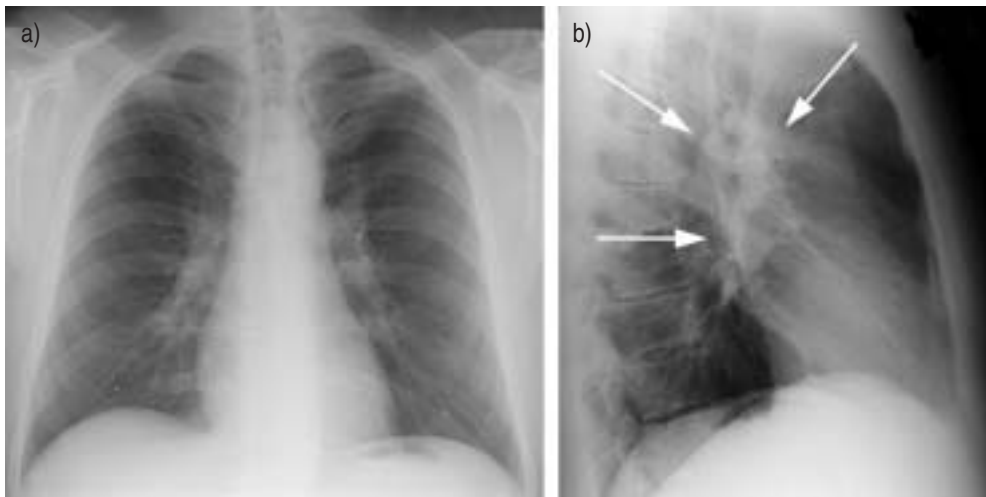


Fig. 1. – a) Posteroanterior and b) lateral chest radiographs of a patient with stage I sarcoidosis. Notice the prominence of the hilae on the posteroanterior radiograph. White arrows on the lateral radiograph point to enlarged mediastinal lymph nodes.

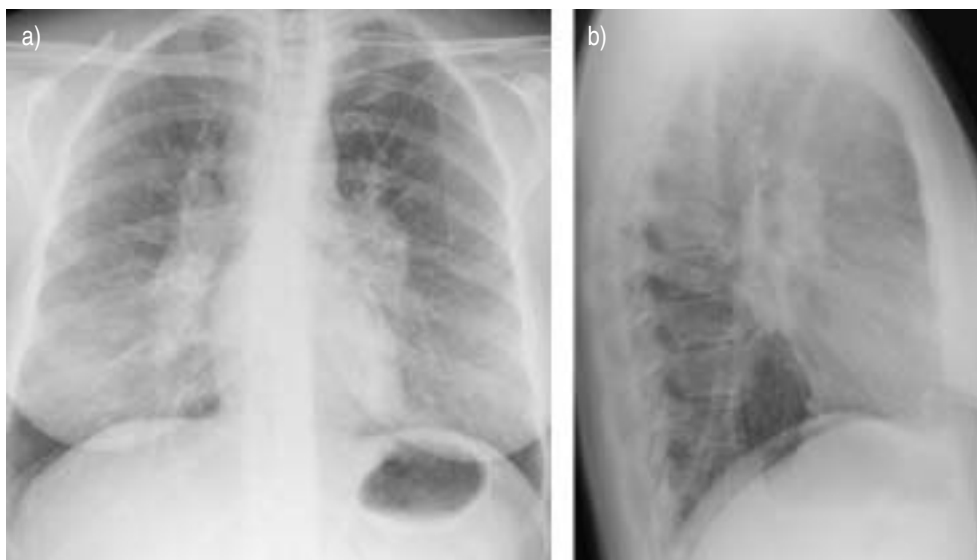


Fig. 2. – a) Posteroanterior and b) lateral chest radiographs of a patient with stage II pulmonary sarcoidosis. Note the prominence of the hilae and enlarged mediastinal lymph nodes. Also seen are increased upper-lobe predominant parenchymal infiltrates.

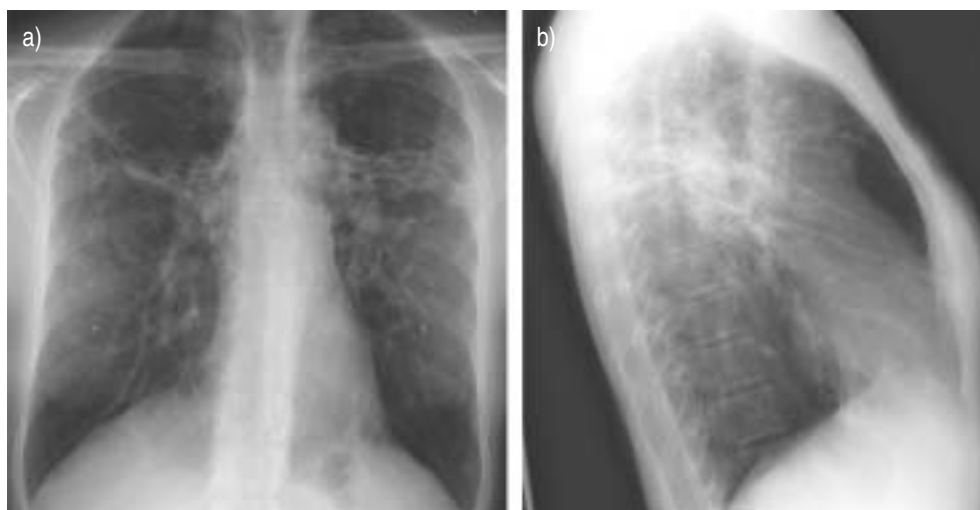


Fig. 3. – a) Posteroanterior and b) lateral chest radiographs of a patient with stage III/IV sarcoidosis. Note the hilar retraction due to thick fibrous bands in the mid-lung fields. No significantly enlarged hilar or mediastinal lymph nodes are seen.

Japanese patients with sarcoidosis, chest radiographs cleared within 3 yrs in 68% [39]. A study of 193 Spanish sarcoidosis patients detected persistent abnormalities on chest radiographs in only 22%, 2 yrs after diagnosis [40]. Failure to remit within 2 yrs predicted a chronic or persistent course [40]. A subsequent Danish study showed that 85% of spontaneous remissions occurred within 2 yrs of presentation [4]. Further, among patients who remained in stage II after 2 yrs of observation, chest radiographs eventually

Table 1. – Radiographic staging of sarcoidosis

Stage	Radiographic Finding
Stage 0	Normal chest radiograph
Stage I	Bilateral hilar/mediastinal lymphadenopathy
Stage II	Bilateral hilar/mediastinal lymphadenopathy plus interstitial infiltrates
Stage III	Interstitial infiltrates without evidence of hilar/mediastinal lymphadenopathy
Stage IV [#]	Dense fibrosis, bullae formation, architectural distortion

Adapted from SCADDING *et al.* [5]. [#]: not included in the original staging schema, and not universally accepted.

normalised in only 12% [4]. A recent prospective study in the USA followed 215 sarcoidosis patients for 2 yrs [10]. In most patients, pulmonary function, radiographic stage, and dyspnoea scale did not change during the 2-yr period. Spirometry worsened in 12%. Only 11 out of 176 (6%) with stage 0, I, or II disease progressed to stage III or IV over the 2-yr follow-up period. A total of 50 patients (23%) developed one or more new organ involvement during that time frame [10].

Differing prognoses between studies may reflect ethnic, geographic, or referral biases [41]. A large cohort of 437 Finnish and 457 Japanese patients were followed for 5 yrs [41]. Chest radiographs normalised within 1 yr in 46% of Japanese but only 16% of Finnish patients. After 5-yr follow-up, the rates were 73% and 40%, respectively ($p < 0.001$). During the 5-yr period, 28 out of 142 (20%) Finnish patients and 43 out of 309 (14%) Japanese patients with initial stage I lesions developed parenchymal infiltrates. At 5 yrs, among patients with initial stage II disease, chest radiographs were normal in 73% of Japanese and 36% of Finnish patients. Among patients with initial stage III disease, chest radiographs had normalised in 35% and 24% of Japanese and Finnish patients, respectively [41].

Additional prognostic factors

Besides the radiographic stages, other clinical factors have prognostic value. The presence of acute inflammatory manifestations (*i.e.*, erythema nodosum, polyarthritis and fever) portend an excellent prognosis, with high rates (>85%) of spontaneous remission [3, 10, 35, 42]. In contrast, factors associated with a poor prognosis and a chronic or relapsing course include: Black race [10, 43–45]; age of onset >40 yrs [3, 40]; hypercalcaemia [3]; extrathoracic disease [3, 43]; lupus pernio [3]; splenomegaly [40]; pulmonary infiltrates on chest radiograph [3, 40]; chronic uveitis, cystic bone lesions, nasal mucosal sarcoidosis [3]; central nervous system and cardiac involvement; and lower annual family income [10].

CT scans

CT scans are superior to conventional chest radiographs in delineating parenchymal, mediastinal, and hilar structures [21, 26, 46, 47]. Characteristic features of sarcoidosis on CT include mediastinal and/or hilar lymphadenopathy, nodular opacities and micronodules along bronchovascular bundles, predilection for mid and upper lung zones, an axial distribution, pleural or subpleural nodules, septal and nonseptal lines, confluent nodular opacities with air-bronchograms (*i.e.*, consolidation), and ground-glass opacities [26, 48] (fig. 4). With advanced disease, architectural distortion, hilar retraction, fibrous bands, bronchiectasis, cystic radiolucencies, bullae, and enlarged

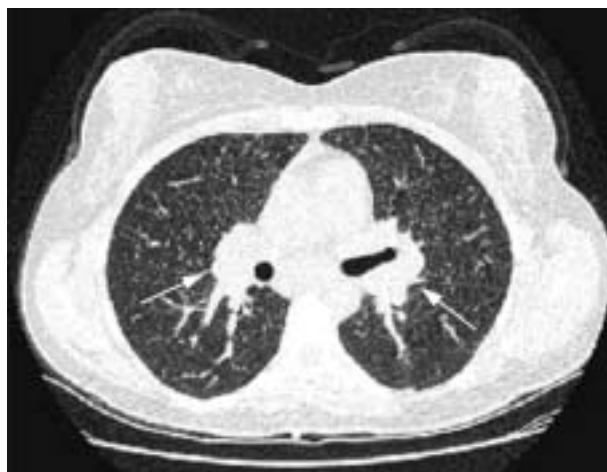

Fig. 4. – High-resolution computed tomography of the chest in a patient with sarcoidosis. Innumerable nodules are seen throughout the parenchyma, involving both upper and lower lobes. Hilar lymph nodes (white arrows) are mildly enlarged.

pulmonary arteries may be observed [22, 26, 49, 50]. Despite the enhanced accuracy of CT, routine CT is not necessary or cost-effective in the management of sarcoidosis [51]. Chest CT scans may be helpful in the following circumstances: atypical clinical or chest radiographic findings [16, 26], or to detect specific complications in the lung (*e.g.*, bronchiectasis, aspergilloma, pulmonary fibrosis, superimposed infection or malignancy). In a study by REMY-JARDIN *et al.* [52], no correlation was found between CT features and bronchoalveolar lavage (BAL) or other parameters of disease activity, either at presentation or at follow-up [52]. Furthermore, findings on initial CT scan have limited prognostic value, since the disease has potential to evolve over time. Despite these limitations, high-resolution thin-section CT (HRCT) may be helpful in selected patients with stage II or III disease to discriminate active inflammation from fibrosis. Nodules, ground-glass opacities, consolidation, or alveolar opacities suggest granulomatous inflammation, which may reverse with therapy [53, 54]. In contrast, honeycomb change, cysts, coarse broad bands, distortion, or traction bronchiectasis indicate irreversible fibrosis [49, 55]. The salient features and role of CT in the management of sarcoidosis are addressed in chapter 18 of this monograph.

Pulmonary function tests in sarcoidosis

Aberrations in pulmonary function tests (PFTs) are present in ~20% of patients with radiographic stage I sarcoidosis, but in 40–80% of patients with parenchymal infiltrates (stages II, III, or IV) [2–4, 33, 56, 57]. Reductions in lung volumes (*e.g.*, vital capacity (VC) and total lung capacity (TLC)) are characteristic; the DL_{CO} is often reduced, but is less pronounced in sarcoidosis than in IPF [2, 58]. Even in the setting of a normal chest radiograph (stage 0), reductions in FVC or DL_{CO} occur in 15–25% and 25–50% of patients, respectively [56, 59]. Oxygenation is usually preserved until late in the course of sarcoidosis [2].

Airflow obstruction (*e.g.*, reduced FEV₁ and expiratory flow rates) and bronchial hyperreactivity occur in 30–50% of sarcoid patients with pulmonary parenchymal involvement [57, 59–61]. In one study of 107 patients with newly diagnosed sarcoidosis,

the FEV₁/FVC ratio was reduced in 61 patients (57%), reductions in *DL*_{CO} were noted in 29 (27%), but only seven (6%) manifested restriction [59]. Airflow obstruction was more frequent with worsening radiographic stage. In another study of 18 patients with sarcoidosis, all of whom had reduced lung volumes or *DL*_{CO}, concomitant airways obstruction was present in all 18 when sensitive tests were employed (*e.g.*, frequency dependence of compliance, airway resistance, closing volumes) [62]. Airflow obstruction may be suggested on CT when bronchial mural thickening, small airway narrowing, or patchy air trapping is present [63–65]. Patients with advanced pulmonary sarcoidosis (radiographic stages III or IV) may exhibit severe decrements in FEV₁/FVC [57]. VISKUM and VESTBO [66] noted a higher mortality risk (OR=1.9) among sarcoid patients with a percentage of predicted (% pred) FEV₁/FVC ratio <70% compared with patients with >70% pred. Airflow obstruction may reflect narrowing of bronchial walls (*via* granulomatous lesions or fibrotic scarring) [67–69]; peribronchiolar fibrosis [70]; compression by enlarged lymph nodes [2]; airway distortion caused by pulmonary fibrosis [57, 71]; small airways disease [59, 62, 72]; or bronchial hyperreactivity [17]. Increased airway hyperreactivity in response to methacholine has been noted in patients with sarcoidosis [73, 74]. In one study, 50% of patients with stage I or II sarcoidosis exhibited bronchial hyperreactivity following methacholine challenge [17]. Clinically, this may manifest as chronic, hacking cough. The mechanism of this bronchial hyperreactivity has not been elucidated, but likely reflects granulomatous inflammation involving the bronchial mucosa [67]. Clinical bronchiectasis is a rare complication of stage IV sarcoidosis [75].

Impaired inspiration muscle endurance (IME) was noted in sarcoid patients with normal lung function compared with healthy controls [76]. Recently, BRANCALEONE *et al.* [77] corroborated reductions in IME in a cohort of sarcoid patients that correlated with impairments in health-related QoL.

Alterations in cardiopulmonary exercise tests (CPETs) have been noted in 28–47% of patients with sarcoidosis [71, 78–80]. Typical aberrations include ventilatory limitation, increased dead space/tidal volume (VT) or widened alveolar-arterial O₂ gradient with exercise [71, 78]. CPETs may be abnormal when static PFTs are normal [71, 75]. In one study of 30 sarcoidosis patients with normal spirometry, ventilatory abnormalities were noted during maximal exercise testing in 14 (47%) [71]. A prospective study of 19 sarcoid patients with normal PFTs (including *DL*_{CO}) and normal echocardiograms noted reductions in maximal workload, maximal oxygen consumption (*V*'O_{2,max}), VT and heart rate compared with age- and sex-matched healthy sedentary controls [75]. Exercise limitation in sarcoidosis patients without pulmonary impairment could reflect an impaired heart rate response to exercise.

Exercise-induced desaturation usually correlates with reductions in *DL*_{CO} [71, 79, 81, 82]. KARETZKY and MCDONOUGH [79] found that *DL*_{CO}<55% had a high sensitivity (85%) and specificity (91%) in predicting a fall in arterial oxygen tension (*P*_{a,O₂}) with exercise in patients with pulmonary sarcoidosis [79]. Arterial desaturation and *DL*_{CO} correlate with the extent and severity of sarcoidosis as assessed by CT [81]. In a recent study, alveolar membrane diffusing capacity and *DL*_{CO} were the strongest predictors of gas exchange abnormalities during exercise [83]. In contrast, neither lung volumes nor expiratory flow rates correlated with exercise gas exchange parameters [83]. Arterial desaturation with exercise is rare in patients with radiographic stage I disease or preserved *DL*_{CO} [82].

One study of patients with mild pulmonary sarcoidosis noted abnormalities on CPETs in nine out of 20 patients (45%) [78]. Reduced *V*'O_{2,max} at the anaerobic threshold was low, and/or the rate of increase of *V*'O_{2,max} was abnormal relative to work rate or heart rate, suggesting a defect in cardiac circulatory function. Resting and exercise echocardiography revealed normal left ventricular function in all patients, but right

ventricular dysfunction or hypertrophy was evident in five. Abnormal response of $\dot{V}O_{2,\max}$ during exercise may reflect subclinical right heart dysfunction.

Although CPETs is more sensitive than static PFTs in predicting work and exercise capacity, the practical value of CPETs is limited. Spirometry and oximetry are usually adequate to follow the course of the disease. For patients with more severe disease, a noninvasive 6-minute walk test provides additional quantitative data.

Physiological aberrations correlate only roughly with histological severity of the disease [70, 84–87]. Three quantitative morphometric studies of 162 open lung biopsies from patients with sarcoidosis found that no physiological parameter predicted the histologic severity of the disease [70, 85, 86]. Mean values of physiological parameters were lower among patients with advanced fibrosis and least deranged with mild disease, but the degree of overlap was considerable. Importantly, none of the physiological parameters discriminate alveolitis (which might be amenable to therapy) from irreversible fibrosis [86, 87].

The extent of pulmonary physiological impairment correlates with severity of disease by chest radiographs [88–91] or CT scanning [21, 22, 52, 90], but correlations are imprecise. The extent of disease on CT scans correlates only modestly with functional impairment [22, 52, 90]. Correlations between physiological parameters and HRCT are improved when semi-quantitative scoring systems are applied [52, 90, 92, 93]. Semi-quantitative scores from CT scans correlated inversely with FVC ($r=-0.81$) and to a lesser extent, with DL_{CO} ($r=-0.49$) [21]. HANSELL *et al.* [94] confirmed inverse correlations between a reticular pattern on HRCT scan and several physiological parameters (*i.e.*, FVC, FEV₁, FEV₁/FVC, and DL_{CO}) [94]. MUERS *et al.* [92] noted that reticular and fibrotic abnormalities on HRCT scan correlated modestly with physiological aberrations, but mass lesions or confluence did not. The pattern of CT may reflect underlying pathology. A honeycomb pattern is most often associated with restriction and low DL_{CO} , whereas bronchial distortion is usually associated with lower expiratory flow rates [50]. A linear pattern was associated with the least functional impairment [50]. More recently, DRENT *et al.* [95] found that HRCT correlated with several physiological parameters (*i.e.*, FEV₁, FVC, DL_{CO} , maximum Pa_{O_2}), and was more sensitive than chest radiographs in detecting pulmonary disability or abnormal gas exchange [95]. In the study by DRENT *et al.* [95], specific findings on CT (*e.g.*, thickening or irregularity of bronchovascular bundles, intra-parenchymal nodules, septal and nonseptal lines, and focal pleural thickening) correlated with pulmonary functional impairment, whereas other features (*e.g.*, focal consolidations, ground-glass opacities, or enlarged lymph nodes) were of minor importance [95]. One recent study examined initial and follow-up HRCT scans in 40 patients with pulmonary sarcoidosis [96]. Predominantly nodular or multiple large nodules disappeared or decreased in size at follow-up. A conglomeration pattern shrank and evolved into bronchial distortion and a decline in FEV₁/FVC ratio [96]. Interestingly, ground-glass opacities and consolidation evolved into honeycombing, and were associated with a decline in FVC [96]. Given the imprecise correlations between CT and physiological parameters, direct measurement of PFTs is critical to assess the extent and degree of pulmonary functional impairment.

Influence of pulmonary function on prognosis

Although physiological parameters at the onset do not predict long-term outcome in patients with sarcoidosis [56, 97–99], mortality is higher among patients with severe physiological impairment [11]. Sequential studies are important to follow the course of the disease and assess response to therapy. Several studies have shown that VC improves

more frequently than DL_{CO} [56, 100, 101], TLC [102], or arterial oxygenation [87]. Importantly, changes in VC and DL_{CO} are usually concordant (in the same direction); discordant (opposite direction) changes occur in <5% of patients [10, 87]. A recent prospective study in the USA found excellent concordance between changes in FVC and FEV₁ in a cohort of 193 sarcoidosis patients [10]. Changes in FVC and FEV₁ were concordant in 155 patients (80.3%) but were never discordant. Measurement of oxygen saturation at rest or during exercise is no more sensitive than VC or DL_{CO} [87]. Given the variability of DL_{CO} [56], and the expense of obtaining lung volumes, spirometry and flow-volume loops are the most useful and cost-effective parameters to follow the course of the disease. Additional studies, such as DL_{CO} , TLC, or gas exchange have a role in selected patients.

Criteria for assessing "response" or improvement have not been validated. Most investigators define a change in FVC >10–15% or DL_{CO} >20% as significant [87, 103]. Responses to therapy are usually evident within 6–12 weeks of initiation of therapy [56, 104].

Laboratory features

Serum angiotensin converting enzyme (ACE) is increased in 30–80% of patients with sarcoidosis, and may be a surrogate marker of total granuloma burden [2, 105]. False positives are noted in <20% of patients with other pulmonary disorders. However, ACE may be normal in patients with active disease. The present authors believe ACE provides ancillary information when the activity of sarcoidosis is uncertain on clinical grounds. However, ACE should never be used in isolation to dictate therapeutic interventions. More recently, ROTHKRANTZ-KOS *et al.* [106] found that serum levels of soluble interleukin (IL)-2 receptor (sIL-2R) appeared to be more useful for monitoring disease severity in sarcoidosis. Moreover, others have demonstrated that extrapulmonary manifestations of sarcoidosis are accompanied by increases in sIL-2R, suggesting that sIL-2R may serve as a marker of disease activity [107].

Historically, the Kveim-Siltzbach skin test was used to diagnose sarcoidosis [108]. The current authors see no current clinical role for the Kveim-Siltzbach skin test [109].

BAL in sarcoidosis

Interaction between alveolar macrophages and T-helper (Th) CD4⁺ cells leads to a Th1-skewed cytokine profile that drives the granulomatous process [109]. Lung T-cells from patients with sarcoidosis spontaneously release Th1 cytokines, such as interferon (IFN)- γ [110] and IL-2 [111].

Clinical manifestations of pulmonary sarcoidosis depend on the intensity of alveolar inflammation. In some cases, the alveolitis remains subclinical, whereas others present with cough, dyspnoea, or chest pain. Alveolitis in sarcoidosis reflects a local expression of a disseminated immunological reaction. Interestingly, in cases of extrathoracic sarcoidosis where pulmonary symptoms are clinically lacking, features of an alveolitis suspicious for sarcoidosis can be found, and, therefore, BAL fluid analysis may be of additional diagnostic value [112]. Typically, BAL fluid in pulmonary sarcoidosis reveals lymphocytosis, low or normal granulocytes, and an increased CD4⁺/CD8⁺ ratio [113–115]. These features are not specific, as there is overlap between other interstitial lung disorders [113, 115]. However, BAL fluid cell profiles may narrow the differential diagnosis [113, 115]. BAL has provided invaluable insight into the pathogenesis of sarcoidosis [109]. Recently, it was demonstrated that the number of polymorphonuclear

neutrophils in BAL fluid is useful to distinguish sarcoidosis patients with a more favourable outcome from those having a more severe course [116, 117]. Furthermore, increased numbers of mast cells in BAL fluid [73, 118] were associated with a worse prognosis in some studies, but significant variability exists.

Most studies have found no significant correlations between initial BAL CD4+/CD8+ ratios and subsequent outcome or response to therapy. In fact, intense alveolitis is characteristic of Löfgren's syndrome, which spontaneously remits in >85% of patients [114, 119, 120]. Provided its limitations are kept in mind and considered in the context of information gained from conventional ancillary diagnostic tests, together with a thorough clinical evaluation, there appears to be a place for BAL in the diagnostic work-up of pulmonary inflammation, including sarcoidosis.

Radionuclide techniques

Radionuclide techniques (*e.g.*, ⁶⁷gallium (Ga) citrate [121, 122]), scintigraphy with somatostatic analogues (¹¹¹In-pentetreotide [123] or ^{99m}technetium-labelled depreotide [124]) or fluoro-2-deoxyglucose positron emission tomography scans [125–127] have been employed to diagnose or stage sarcoidosis. The role of these techniques is reviewed in depth in chapter 19 of this monograph.

Diagnosis of pulmonary sarcoidosis

Flexible fiberoptic bronchoscopy with transbronchial lung biopsy (TBLB) achieves diagnostic yields of 60–90%, even among patients with radiographic stage I disease [128, 129]. Transbronchial needle aspiration biopsies (TBNA) with Wang 18-, 19- or 22-gauge cytology needles are diagnostic in 63–90% of patients with mediastinal and/or hilar adenopathy on chest CT [23, 130–135]. The combination of TBNA and TBLB may have a higher yield than either procedure alone [136]. Diagnostic cytological criteria for sarcoidosis by TBNA include: the presence of epithelioid cell granulomas, lymphocytes, clusters or palisading epithelioid histiocytes, multinucleated giant cells with no or minimal necrosis; and negative stains for fungi and acid-fast bacteria [23, 134]. Damage to the bronchoscope may complicate TBNA, particularly when performed by individuals with limited experience [137]. One study suggested that fine-needle aspiration (FNA) is underutilised to diagnose sarcoidosis and is cost-effective [138].

Mediastinal lymph node biopsies

CT-guided transthoracic FNA, with or without core needle biopsy, may be useful to diagnose malignant or benign lesions involving mediastinal or subcarinal lymph nodes (yields up to 78%) [139]. Complications of transthoracic FNA include pneumothoraces (10–60%) and haemoptysis (5–10%) [139]. Severe bleeding is rare, but has been described with core biopsy. Endoscopic ultrasound (EUS)-guided FNA has been used to diagnose mediastinal masses, primarily in patients with suspected malignancy [140], but experience is limited in patients with sarcoidosis [141]. EUS gives an excellent overview of mediastinal structures, including the paraoesophageal space, aortopulmonary window, subcarinal region [142].

Surgical procedures to access mediastinal nodes include: 1) cervical mediastinoscopy [143–145]; the Chamberlain procedure (a parasternal mini-thoracotomy to biopsy

aortopulmonary window or para-aortic nodes), and video-assisted thoracoscopic surgical biopsy (VATS). Currently, VATS can be performed safely in an outpatient setting [146, 147] and is preferred over traditional thoracotomy.

Specific complications of intrathoracic sarcoidosis

Necrotising sarcoid angiitis

Necrotising sarcoid angiitis and granulomatosis, initially described by LIEBOW in 1973 [148], is a variant of sarcoidosis characterised by pulmonary vasculitis, granulomas, and pulmonary nodules on chest radiographs [149–153]. Histological features include: 1) a granulomatous vasculitis involving arteries and veins; 2) confluent non-necrotising granulomata involving the bronchi, bronchioles, and lung; 3) variable degrees of fibrosis; and 4) extensive parenchymal necrosis [149, 152]. Systemic vasculitis does not occur. Clinical and radiographic features of necrotising sarcoid angiitis and granulomatosis are similar to "nodular sarcoid" [28, 154–156]. Cardinal histological features of nodular sarcoidosis are focal nodules composed of masses of granulomas and hyalinised connective tissue [154]. The present authors believe that necrotising sarcoid angiitis and nodular sarcoid are simply variants of sarcoidosis. Prognosis of these entities is generally excellent. The disease resolves (either spontaneously or in response to therapy) in most patients.

Bronchostenosis

Stenosis or compression of bronchi may result from granulomatous inflammation of the bronchial wall, extrinsic compression from enlarged hilar nodes, or distortion of major bronchi caused by end-stage parenchymal sarcoidosis [68, 69, 157–159]. Atelectasis of involved lobes or segments (particularly the right middle lobe) may result [157, 158, 160–162]. Bronchostenosis was detected in 2–26% of patients with sarcoidosis undergoing bronchoscopy in two studies [68, 159]. One retrospective study of 2,500 patients with sarcoidosis identified 18 patients with >50% stenosis of proximal bronchi [69]. Three bronchoscopic patterns were observed, including single focal stenosis, multiple focal stenoses and diffuse narrowing of the bronchial tree [69]. The bronchial mucosa appeared oedematous and inflamed at the site of stenosis in all cases. Endobronchial biopsies showed noncaseating granulomata in 77% of patients [69]. Typical clinical features of proximal endobronchial stenosis include dyspnoea, cough, wheezing and extrapulmonary manifestations [68, 69]. Wheezing, high-pitched inspiratory "squeaks", or stridor may be evident on chest auscultation in patients with symptomatic bronchostenosis [68]. Helical CT scans are useful to determine the extent and nature of stenotic lesions in the lower respiratory tract [63], but false positive results were noted in 8% [63] and 14% [163] of cases in two series. Early initiation of corticosteroid therapy may be efficacious in ameliorating symptoms and pulmonary dysfunction. Conversely, delay in therapy may result in acquired fixed stenoses and persistent ventilatory defects [69]. Dilatation of endobronchial stenoses may provide relief in patients who are refractory to medical therapy [164].

Mycetomas

Mycetomas (typically due to *Aspergillus* spp.) may develop in cystic spaces (typically in the upper lobes) in patients with advanced (radiographic stage III or IV) sarcoidosis

[165–167]. Ipsilateral pleural thickening usually antedates the fungus ball or air-crescent sign [168]. Mycetomas are often asymptomatic, but fatal haemorrhage can occur when *Aspergillus* invades vessel walls [161, 166, 169]. Surgical resection is advised for localised lesions in patients able to tolerate surgery [165–167]. However, surgery may be contraindicated in patients with severe parenchymal disease or extensive pleural adhesions [166, 167]. In such cases, topical or intracavitary therapy has been tried, with anecdotal successes, but experience is limited [170, 171]. Systemic antifungal therapy is of unproven value. Bronchial embolisation has been successful to control intractable bleeding [165].

Pleural involvement in sarcoidosis

Clinically-significant pleural manifestations (*e.g.*, pneumothorax, pleural effusions, chylothorax, or pleural thickening) occur in 2–4% of patients with sarcoidosis [27, 172–174]. Sarcoid pleural effusions may be either transudative or exudative; lymphocytosis occurs in two-thirds of cases [27, 172]. Pneumothorax may complicate advanced fibrocystic sarcoidosis [173]. Chylothorax is a rare complication of sarcoidosis (only a few cases have been described) [2, 175–177].

Pulmonary vascular involvement in sarcoidosis

As sarcoid granulomatous lesions follow pulmonary vessels, incidental histological involvement is common, noted in 42–89% of open lung biopsies from patients with pulmonary sarcoidosis [70, 178]. However, clinically significant pulmonary vascular involvement is uncommon. PAH has been noted in 1–5% of patients with sarcoidosis [179–183]. The incidence is considerably higher among patients with advanced fibrocystic sarcoidosis [184–187]. Mechanism(s) responsible for PAH in sarcoidosis probably include: 1) hypoxic vasoconstriction [180]; 2) infiltration and/or obliteration of the pulmonary vasculature by the granulomatous, fibrotic response [188]; and/or 3) extrinsic compression of major pulmonary arteries by enlarged lymph nodes [179]. In one study of patients with stage III sarcoidosis, pulmonary artery (PA) pressures were elevated in 50% of patients at rest and 100% during exercise [184]. Chest CT scans may be useful to predict the presence of PAH in patients with parenchymal lung disease [189]. CT features which suggest PAH include: main PA diameter >29 mm; segmental artery-to-bronchus ratio >1:1 in three out of four lobes [189]; ratio of the diameter of the main PA and of the ascending aorta >1 [190]. Two recent studies evaluated PA pressures in patients with end-stage pulmonary sarcoidosis awaiting lung transplantation (LT) [185–187]. Pulmonary hypertension was an independent predictor of mortality among patients with sarcoidosis listed for LT [185, 187]. The role of vasodilators in sarcoidosis-associated PAH has not been elucidated, but short- and long-term responses were noted in case reports [180] or small series [188, 191].

Other rare vascular complications of sarcoidosis (limited to a few case reports) include: pulmonary arterial stenoses from granulomatous involvement of the vessels [192, 193]; extrinsic compression of pulmonary arteries by enlarged hilar lymph nodes [194, 195] or fibrosing mediastinitis [2]; and pulmonary veno-occlusive disease (resulting from obstruction of interlobular septa veins by granulomata or perivascular fibrosis) [196, 197].

Superior vena cava syndrome

Rarely, extensive fibrosis of mediastinal or vascular structures results in narrowing or obstruction of innominate veins [198], superior vena cava (SVC) [199], or bronchi [200] in

patients with sarcoidosis. The current authors are aware of only six published cases of SVC syndrome complicating sarcoidosis [193, 199, 201–204]. Extensive mediastinal lymphadenopathy compressing the SVC was a universal feature.

Pulmonary embolism

Sarcoidosis involving the lung has been linked to pro-coagulant activity in BAL fluid [205], and published case reports have described patients with sarcoidosis and vascular thrombosis in the absence of known risk factors [206, 207], thus, raising the question of an association between sarcoidosis and venous thromboembolic disease. To the best of the present authors' knowledge, no reports defining such an association have been published. However, the presentation of sarcoidosis is known to mimic acute pulmonary embolism. Numerous case reports have described patients presenting with acute onset chest pain and dyspnoea accompanied by ventilation-perfusion studies, suggestive of pulmonary embolism [208–212]. Subsequent evaluation (with either pulmonary angiogram or ^{67}Ga scanning) demonstrated evidence of pulmonary (and, in some cases, extrapulmonary) sarcoidosis with compression of lobar or segmental pulmonary arteries by enlarged lymph nodes. Furthermore, serological testing for D-dimer in suspected pulmonary embolism may potentially confound the diagnosis of sarcoidosis. In one study of 28 patients with newly diagnosed sarcoidosis, SHORR and HNATIUK [213] observed elevated D-dimer titres (as assessed by latex agglutination) in 11 (39.3%) subjects. These investigators also noted a positive correlation among elevated D-dimer titres (defined as $>1:2$), interstitial involvement with sarcoidosis, lower DL_{CO} , elevated serum ACE levels, and presence of dyspnoea [213]. Hence, these data suggest that sarcoidosis should be considered in the differential diagnosis of acute pulmonary embolism.

Sarcoidosis in HIV-infected patients

Sarcoidosis (pulmonary or extrapulmonary) may rarely complicate HIV infection [214–217]. Chest radiographic [214] and histological [218] findings are similar to sarcoidosis in non-HIV infected patients. Most cases of sarcoidosis in HIV-infected patients developed after beginning highly active antiretroviral therapy (HAART) [214, 217–220], but sarcoidosis can occur prior to institution of HAART [214, 221]. Intense CD4+ alveolitis on BAL fluid analysis was noted in two HIV-infected patients receiving HAART [218], whereas earlier reports of sarcoidosis complicating HIV cited CD8+ alveolitis [222]. A retrospective study of seven patients with sarcoidosis and HIV infection noted that CD4+ lymphocyte counts exceeded $200\text{ cells}\cdot\mu\text{L}^{-1}$ in all patients [223], suggesting that CD4+ lymphocytes were instrumental to the granulomatous process.

Sarcoidosis complicating type-1 interferon therapy

Type 1 IFNs (*e.g.*, IFN- α or IFN- β), used to treat viral hepatitis, multiple sclerosis, and diverse autoimmune and malignant disorders, may evoke a Th1 lymphocyte bias and thereby amplify granulomatous inflammation [224, 225]. Although uncommon, new-onset or recurrent sarcoidosis may complicate IFN- α or IFN- β therapy [224–230]. Most cases remit with IFN withdrawal or dose reduction, but corticosteroids are required in some patients [225, 231].

Treatment of sarcoidosis

Treatment of sarcoidosis remains controversial. Corticosteroids (CS) are the cornerstone of therapy for severe or progressive sarcoidosis (pulmonary or extrapulmonary), and often produce dramatic resolution of the disease [33, 232]. The long-term benefit of CS therapy is less clear, as relapses may occur upon taper or cessation of therapy [44, 45, 233]. A few prospective, randomised studies found no long-term benefit with CS among patients with pulmonary sarcoidosis [103, 234–238]. However, these studies included patients with normal or near normal pulmonary function, and the rates of spontaneous remissions were high. Patients with severe or progressive disease were excluded from these studies. Interpretation of efficacy of therapy is confounded by heterogeneous patient populations, a high rate of spontaneous remissions, differing doses and duration of therapy, inability to discriminate the effects of therapy from the natural history of the disease, and lack of validated standards for disease activity. A multicentre, prospective, randomised trial sponsored by the British Thoracic Society supports the use of CS for patients with chronic persistent radiographic infiltrates [36]. In the study by GIBSON *et al.* [36], patients with stage II or III sarcoidosis and persistent radiographic infiltrates after 6 months of observation were randomised to prednisolone or no therapy. At long-term follow-up, PFTs improved in the CS-treated cohort. Thus, CS may attenuate loss of pulmonary function, even in asymptomatic patients. Extensive clinical experience suggests that CS are efficacious in patients with active, symptomatic disease involving lungs or extrapulmonary organs [1, 33, 44]. The decision to treat requires a careful assessment of acuity and severity of disease, likelihood of spontaneous remission, and risks associated with therapy. Treatment should be circumscribed and focused. Treatment is rarely appropriate for stage I disease, but a trial of CS is reasonable in symptomatic patients with progressive or persistent pulmonary infiltrates or significant physiological dysfunction. Alternative therapeutic modalities are reserved for patients failing or experiencing adverse effects from CS [1, 232, 239–245]. Medical treatment of sarcoidosis is discussed in detail in chapter 20 of this monograph.

Lung transplantation for sarcoidosis

LT (either single or bilateral) is a viable option for patients with end-stage pulmonary sarcoidosis refractory to medical therapy [186]. Registry data from the International Society for Heart and Lung Transplantation (ISHLT) noted that sarcoidosis was the indication for lung transplantation in 287 patients (2.6% of all lung transplants performed from 1995 to June 2003) [246]. Mortality rates among sarcoidosis patients awaiting transplantation are high (27–53%) [185, 187]. ARCASOY *et al.* [185] analysed 43 patients with sarcoidosis awaiting LT. Mean PA pressure was an independent predictor of death. Further, right atrial pressure >15 mmHg conferred a 5.2-fold increase in mortality [185]. In one study of sarcoid patients listed for transplant, Black race and increased severity of illness were independent predictors of 30-day mortality [186]. In a subsequent retrospective study of all patients in the USA listed for LT, the following parameters were independently associated with increased mortality: Black race, the amount of supplemental oxygen used and mean PA pressures [187]. Surprisingly, PFTs did not correlate with mortality. These investigators correctly noted that data predicting mortality for other types of interstitial lung diseases may not apply to sarcoidosis [187]. Short- and late-term mortality rates following LT for sarcoidosis were higher compared with lung transplants performed for other diseases [186, 246]. Data from the ISHLT cited 1-, 3-, and 5-yr survival rates of 67%, 53% and 45%, respectively, among sarcoidosis

patients undergoing LT [246]. In a retrospective review of experience in the USA from 1995–2000, 30-day survival post-lung transplant was 83% among 133 patients with sarcoidosis compared with 91% among LT recipients for other conditions ($p=0.002$) [247]. Others authors cited worse outcomes among African Americans receiving kidney [248] or liver transplants [249]; this may reflect greater major histocompatibility polymorphisms or immunological hyperresponsiveness among African Americans.

Recurrent non-necrotising granulomas have been noted in the transplanted allografts in up to 35% of patients [250–252], but are not usually associated with symptoms [252]. Although data are sparse, the presence of mycetomas was associated with a worse prognosis post-transplant [253], and is considered by many centres to be a contra-indication to performing LT.

Summary

Sarcoidosis is a multi-systemic inflammatory disorder, but affects the lungs in ~90% of cases. Nonproductive cough, dyspnoea and chest pain are the most common features of pulmonary sarcoidosis.

The diagnosis of pulmonary sarcoidosis is suggested by bilateral hilar lymphadenopathy, with or without parenchymal changes, on chest radiographs, and is supported by noncaseating granulomata in tissue biopsies. Radiographic staging of pulmonary sarcoidosis, as well as clinical and laboratory findings can be prognostic.

Treatment of pulmonary sarcoidosis typically includes corticosteroids, but other therapeutic agents may have benefit, and treatment needs to be individualised. Lung transplantation remains a viable therapeutic alternative for patients who do not respond to pharmaceutical agents.

Keywords: Corticosteroids, interstitial lung disease, lung transplantation, lymphadenopathy, transbronchial lung biopsy.

References

1. Lynch 3rd J, Baughman R, Sharma O. Extrapulmonary sarcoidosis. *Semin Respir Infect* 1998; 13: 229–254.
2. Lynch 3rd JP, Kazerooni EA, Gay SE. Pulmonary sarcoidosis. *Clin Chest Med* 1997; 18: 755–785.
3. Neville E, Walker A, James DG. Prognostic factors predicting the outcome of sarcoidosis: An analysis of 818 patients. *Q J Med* 1983; 208: 525–533.
4. Romer FK. Presentation of sarcoidosis and outcome of pulmonary changes. *Dan Med Bull* 1982; 29: 27–32.
5. Scadding J. Prognosis of intrathoracic sarcoidosis in England: a review of 136 cases after five years' observation. *BMJ* 1961; 2: 1165–1172.
6. Hillerdal G, Nou E, Osterman K, Schmekel B. Sarcoidosis: epidemiology and prognosis. A 15-year European study. *Am Rev Respir Dis* 1984; 130: 29–32.
7. Henke CE, Henke G, Elveback LR, Beard CM, Ballard DJ, Kurland LT. The epidemiology of sarcoidosis in Rochester, Minnesota: a population-based study of incidence and survival. *Am J Epidemiol* 1986; 123: 840–845.
8. Reich JM, Johnson RE. Course and prognosis of sarcoidosis in a nonreferral setting. Analysis of 86 patients observed for 10 years. *Am J Med* 1985; 78: 61–67.

9. Reich JM. Mortality of intrathoracic sarcoidosis in referral vs population-based settings: influence of stage, ethnicity, and corticosteroid therapy. *Chest* 2002; 121: 32–39.
10. Judson MA, Baughman RP, Thompson BW, et al. Two year prognosis of sarcoidosis: the ACCESS experience. *Sarcoidosis Vasc Diffuse Lung Dis* 2003; 20: 204–211.
11. Baughman RP, Winget DB, Bowen EH, Lower EE. Predicting respiratory failure in sarcoidosis patients. *Sarcoidosis Vasc Diffuse Lung Dis* 1997; 14: 154–158.
12. Huang CT, Heurich AE, Sutton AL, Lyons HA. Mortality in sarcoidosis. A changing pattern of the causes of death. *Eur J Respir Dis* 1981; 62: 231–238.
13. Perry A, Vuitch F. Causes of death in patients with sarcoidosis. A morphologic study of 38 autopsies with clinicopathologic correlations. *Arch Pathol Lab Med* 1995; 119: 167–172.
14. Siltzbach LE, James DG, Neville E, et al. Course and prognosis of sarcoidosis around the world. *Am J Med* 1974; 57: 847–852.
15. Gideon NM, Mannino DM. Sarcoidosis mortality in the United States 1979–1991: an analysis of multiple-cause mortality data. *Am J Med* 1996; 100: 423–427.
16. Statement on sarcoidosis. Joint Statement of the American Thoracic Society (ATS), the European Respiratory Society (ERS) and the World Association of Sarcoidosis and Other Granulomatous Disorders (WASOG) adopted by the ATS Board of Directors and by the ERS Executive Committee, February 1999. *Am J Respir Crit Care Med* 1999; 160: 736–755.
17. Bechtel JJ, Starr T 3rd, Dantzker DR, Bower JS. Airway hyperreactivity in patients with sarcoidosis. *Am Rev Respir Dis* 1981; 124: 759–761.
18. Lynch 3rd JP, Wurfel M, Flaherty K, et al. Usual interstitial pneumonia. *Semin Resp Crit Care Med* 2001; 22: 357–387.
19. De Vries J, Rothkrantz-Kos S, van Dieijen-Visser MP, Drent M. The relationship between fatigue and clinical parameters in pulmonary sarcoidosis. *Sarcoidosis Vasc Diffuse Lung Dis* 2004; 21: 127–136.
20. Wirnsberger RM, De Vries J, Breteler MH, van Heck GL, Wouters EF, Drent M. Evaluation of quality of life in sarcoidosis patients. *Respir Med* 1998; 92: 750–756.
21. Bergin CJ, Bell DY, Coblentz CL, et al. Sarcoidosis: correlation of pulmonary parenchymal pattern at CT with results of pulmonary function tests. *Radiology* 1989; 171: 619–624.
22. Brauner MW, Grenier P, Mompoin D, Lenoir S, de Cremoux H. Pulmonary sarcoidosis: evaluation with high-resolution CT. *Radiology* 1989; 172: 467–471.
23. Cetinkaya E, Yildiz P, Altin S, Yilmaz V. Diagnostic value of transbronchial needle aspiration by Wang 22-gauge cytology needle in intrathoracic lymphadenopathy. *Chest* 2004; 125: 527–531.
24. Packe GE, Ayres JG, Citron KM, Stableforth DE. Large lung bullae in sarcoidosis. *Thorax* 1986; 41: 792–797.
25. Zar HJ, Cole RP. Bullous emphysema occurring in pulmonary sarcoidosis. *Respiration* 1995; 62: 290–293.
26. Lynch 3rd JP. Computed tomographic scanning in sarcoidosis. *Semin Resp Crit Care Med* 2003; 24: 393–418.
27. Sharma OP, Gordonson J. Pleural effusion in sarcoidosis: a report of six cases. *Thorax* 1975; 30: 95–101.
28. Rose RM, Lee RG, Costello P. Solitary nodular sarcoidosis. *Clin Radiol* 1985; 36: 589–592.
29. Sharma OP, Hewlett R, Gordonson J. Nodular sarcoidosis: an unusual radiographic appearance. *Chest* 1973; 64: 189–192.
30. Biem J, Hoffstein V. Aggressive cavitary pulmonary sarcoidosis. *Am Rev Respir Dis* 1991; 143: 428–430.
31. Ichikawa Y, Fujimoto K, Shiraishi T, Oizumi K. Primary cavitary sarcoidosis: high-resolution CT findings. *Am J Roentgenol* 1994; 163: 745.
32. Tazi A, Desfemmes-Baleyte T, Soler P, Valeyre D, Hance AJ, Battesti JP. Pulmonary sarcoidosis with a diffuse ground glass pattern on the chest radiograph. *Thorax* 1994; 49: 793–797.
33. Sharma OP. Pulmonary sarcoidosis and corticosteroids. *Am Rev Respir Dis* 1993; 147: Suppl. 6 Pt 1, 1598–1600.

34. Siltzbach LE. Sarcoidosis: clinical features and management. *Med Clin North Am* 1967; 51: 483–502.
35. Mañá J, Gomez-Vaquero C, Montero A, et al. Löfgren's syndrome revisited: a study of 186 patients. *Am J Med* 1999; 107: 240–245.
36. Gibson GJ, Prescott RJ, Muers MF, et al. British Thoracic Society Sarcoidosis study: effects of long term corticosteroid treatment. *Thorax* 1996; 51: 238–247.
37. Hunninghake GW, Gilbert S, Pueringer R, et al. Outcome of the treatment for sarcoidosis. *Am J Respir Crit Care Med* 1994; 149: Suppl. 4 Pt 1, 893–898.
38. Chappell AG, Cheung WY, Hutchings HA. Sarcoidosis: a long-term follow up study. *Sarcoidosis Vasc Diffuse Lung Dis* 2000; 17: 167–173.
39. Nagai S, Shigematsu M, Hamada K, Izumi T. Clinical courses and prognoses of pulmonary sarcoidosis. *Curr Opin Pulm Med* 1999; 5: 293–298.
40. Mañá J, Salazar A, Manresa F. Clinical factors predicting persistence of activity in sarcoidosis: a multivariate analysis of 193 cases. *Respiration* 1994; 61: 219–225.
41. Pietinalho A, Ohmichi M, Lofroos AB, Hiraga Y, Selroos O. The prognosis of pulmonary sarcoidosis in Finland and Hokkaido, Japan. A comparative five-year study of biopsy-proven cases. *Sarcoidosis Vasc Diffuse Lung Dis* 2000; 17: 158–166.
42. Gran JT, Bohmer E. Acute sarcoid arthritis: a favourable outcome? A retrospective survey of 49 patients with review of the literature. *Scand J Rheumatol* 1996; 25: 70–73.
43. Israel HL, Karlin P, Menduke H, DeLisser OG. Factors affecting outcome of sarcoidosis. Influence of race, extrathoracic involvement, and initial radiologic lung lesions. *Ann N Y Acad Sci* 1986; 465: 609–618.
44. Johns CJ, Michele TM. The clinical management of sarcoidosis. A 50-year experience at the Johns Hopkins Hospital. *Medicine (Baltimore)* 1999; 78: 65–111.
45. Gottlieb JE, Israel HL, Steiner RM, Triolo J, Patrick H. Outcome in sarcoidosis. The relationship of relapse to corticosteroid therapy. *Chest* 1997; 111: 623–631.
46. Sider L, Horton ES Jr. Hilar and mediastinal adenopathy in sarcoidosis as detected by computed tomography. *J Thorac Imaging* 1990; 5: 77–80.
47. Hennebicque AS, Nunes H, Brillet PY, Moulahi H, Valeyre D, Brauner MW. CT findings in severe thoracic sarcoidosis. *Eur Radiol* 2005; 15: 23–30.
48. Nishimura K, Itoh H, Kitaichi M, Nagai S, Izumi T. CT and pathological correlation of pulmonary sarcoidosis. *Semin Ultrasound CT MR* 1995; 16: 361–70.
49. Brauner MW, Lenoir S, Grenier P, Cluzel P, Battesti JP, Valeyre D. Pulmonary sarcoidosis: CT assessment of lesion reversibility. *Radiology* 1992; 182: 349–354.
50. Abehsera M, Valeyre D, Grenier P, Jaillet H, Battesti JP, Brauner MW. Sarcoidosis with pulmonary fibrosis: CT patterns and correlation with pulmonary function. *Am J Roentgenol* 2000; 174: 1751–1757.
51. Mañá J, Teirstein AS, Mendelson DS, Padilla ML, DePalo LR. Excessive thoracic computed tomographic scanning in sarcoidosis. *Thorax* 1995; 50: 1264–1266.
52. Remy-Jardin M, Giraud F, Remy J, Wattinne L, Wallaert B, Duhamel A. Pulmonary sarcoidosis: role of CT in the evaluation of disease activity and functional impairment and in prognosis assessment. *Radiology* 1994; 191: 675–680.
53. Muller NL, Miller RR. Ground-glass attenuation, nodules, alveolitis, and sarcoid granulomas. *Radiology* 1993; 189: 31–32.
54. Remy-Jardin M, Giraud F, Remy J, Copin MC, Gosselin B, Duhamel A. Importance of ground-glass attenuation in chronic diffuse infiltrative lung disease: pathologic-CT correlation. *Radiology* 1993; 189: 693–698.
55. Murdoch J, Muller NL. Pulmonary sarcoidosis: changes on follow-up CT examination. *Am J Roentgenol* 1992; 159: 473–477.
56. Alhamad EH, Lynch JP 3rd, Martinez FJ. Pulmonary function tests in interstitial lung disease: what role do they have?. *Clin Chest Med* 2001; 22: 715–750, ix.
57. Sharma OP, Johnson R. Airway obstruction in sarcoidosis. A study of 123 nonsmoking black American patients with sarcoidosis. *Chest* 1988; 94: 343–346.

-
58. Dunn TL, Watters LC, Hendrix C, Cherniack RM, Schwarz MI, King TE Jr. Gas exchange at a given degree of volume restriction is different in sarcoidosis and idiopathic pulmonary fibrosis. *Am J Med* 1988; 85: 221–224.
 59. Harrison BD, Shaylor JM, Stokes TC, Wilkes AR. Airflow limitation in sarcoidosis—a study of pulmonary function in 107 patients with newly diagnosed disease. *Respir Med* 1991; 85: 59–64.
 60. McCann BG, Harrison BD. Bronchiolar narrowing and occlusion in sarcoidosis—correlation of pathology with physiology. *Respir Med* 1991; 85: 65–67.
 61. Stjernberg N, Thunell M. Pulmonary function in patients with endobronchial sarcoidosis. *Acta Med Scand* 1984; 215: 121–126.
 62. Levinson RS, Metzger LF, Stanley NN, *et al.* Airway function in sarcoidosis. *Am J Med* 1977; 62: 51–59.
 63. Lenique F, Brauner MW, Grenier P, Battesti JP, Loiseau A, Valeyre D. CT assessment of bronchi in sarcoidosis: endoscopic and pathologic correlations. *Radiology* 1995; 194: 419–423.
 64. Lavergne F, Clerici C, Sadoun D, Brauner M, Battesti JP, Valeyre D. Airway obstruction in bronchial sarcoidosis: outcome with treatment. *Chest* 1999; 116: 1194–1199.
 65. Gleeson FV, Traill ZC, Hansell DM. Evidence of expiratory CT scans of small-airway obstruction in sarcoidosis. *Am J Roentgenol* 1996; 166: 1052–1054.
 66. Viskum K, Vestbo J. Vital prognosis in intrathoracic sarcoidosis with special reference to pulmonary function and radiological stage. *Eur Respir J* 1993; 6: 349–353.
 67. Benatar SR, Clark TJ. Pulmonary function in a case of endobronchial sarcoidosis. *Am Rev Respir Dis* 1974; 110: 490–496.
 68. Udawadia ZF, Pilling JR, Jenkins PF, Harrison BD. Bronchoscopic and bronchographic findings in 12 patients with sarcoidosis and severe or progressive airways obstruction. *Thorax* 1990; 45: 272–275.
 69. Chambellan A, Turbie P, Nunes H, Brauner M, Battesti JP, Valeyre D. Endoluminal stenosis of proximal bronchi in sarcoidosis: bronchoscopy, function, and evolution. *Chest* 2005; 127: 472–481.
 70. Carrington CB. Structure and function in sarcoidosis. *Ann N Y Acad Sci* 1976; 278: 265–283.
 71. Miller A, Brown LK, Sloane MF, Bhuptani A, Teirstein AS. Cardiorespiratory responses to incremental exercise in sarcoidosis patients with normal spirometry. *Chest* 1995; 107: 323–329.
 72. Radwan L, Grebska E, Kozirowski A. Small airways function in pulmonary sarcoidosis. *Scand J Respir Dis* 1978; 59: 37–43.
 73. Ohrn MB, Skold CM, van Hage-Hamsten M, Sigurdardottir O, Zetterstrom O, Eklund A. Sarcoidosis patients have bronchial hyperreactivity and signs of mast cell activation in their bronchoalveolar lavage. *Respiration* 1995; 62: 136–142.
 74. Manresa Presas F, Romero Colomer P, Rodriguez Sanchon B. Bronchial hyperreactivity in fresh stage I sarcoidosis. *Ann N Y Acad Sci* 1986; 465: 523–529.
 75. Delobbe A, Perrault H, Maitre J, *et al.* Impaired exercise response in sarcoid patients with normal pulmonary function. *Sarcoidosis Vasc Diffuse Lung Dis* 2002; 19: 148–153.
 76. Wirnsberger RM, Drent M, Hekelaar N, *et al.* Relationship between respiratory muscle function and quality of life in sarcoidosis. *Eur Respir J* 1997; 10: 1450–1455.
 77. Brancaleone P, Perez T, Robin S, Nevriere R, Wallaert B. Clinical impact of inspiratory muscle impairment in sarcoidosis. *Sarcoidosis Vasc Diffuse Lung Dis* 2004; 21: 219–227.
 78. Sietsema KE, Kraft M, Ginzton L, Sharma OP. Abnormal oxygen uptake responses to exercise in patients with mild pulmonary sarcoidosis. *Chest* 1992; 102: 838–845.
 79. Karetzky M, McDonough M. Exercise and resting pulmonary function in sarcoidosis. *Sarcoidosis Vasc Diffuse Lung Dis* 1996; 13: 43–49.
 80. Bradvik I, Wollmer P, Blom-Bulow B, Albrechtsson U, Jonson B. Lung mechanics and gas exchange during exercise in pulmonary sarcoidosis. *Chest* 1991; 99: 572–578.
 81. Medinger AE, Khouri S, Rohatgi PK. Sarcoidosis: the value of exercise testing. *Chest* 2001; 120: 93–101.
-

82. Barros WG, Neder JA, Pereira CA, Nery LE. Clinical, radiographic and functional predictors of pulmonary gas exchange impairment at moderate exercise in patients with sarcoidosis. *Respiration* 2004; 71: 367–373.
83. Lamberto C, Nunes H, Le Toumelin P, Duperron F, Valeyre D, Clerici C. Membrane and capillary blood components of diffusion capacity of the lung for carbon monoxide in pulmonary sarcoidosis: relation to exercise gas exchange. *Chest* 2004; 125: 2061–2068.
84. Young RL, Lordon RE, Krumholz RA, Harkleroad LE, Branam GE, Weg JG. Pulmonary sarcoidosis. 1. Pathophysiologic correlations. *Am Rev Respir Dis* 1968; 97: 997–1008.
85. Young RC Jr, Carr C, Shelton TG, et al. Sarcoidosis: relationship between changes in lung structure and function. *Am Rev Respir Dis* 1967; 95: 224–238.
86. Huang CT, Heurich AE, Rosen Y, Moon S, Lyons HA. Pulmonary sarcoidosis: roentgenographic, functional, and pathologic correlations. *Respiration* 1979; 37: 337–345.
87. Winterbauer RH, Hutchinson JF. Use of pulmonary function tests in the management of sarcoidosis. *Chest* 1980; 78: 640–647.
88. McLoud TC, Epler GR, Gaensler EA, Burke GW, Carrington CB. A radiographic classification for sarcoidosis: physiologic correlation. *Invest Radiol* 1982; 17: 129–138.
89. Lin YH, Haslam PL, Turner-Warwick M. Chronic pulmonary sarcoidosis: relationship between lung lavage cell counts, chest radiograph, and results of standard lung function tests. *Thorax* 1985; 40: 501–507.
90. Muller NL, Mawson JB, Mathieson JR, Abboud R, Ostrow DN, Champion P. Sarcoidosis: correlation of extent of disease at CT with clinical, functional, and radiographic findings. *Radiology* 1989; 171: 613–618.
91. Nugent KM, Peterson MW, Jolles H, Monick MM, Hunninghake GW. Correlation of chest roentgenograms with pulmonary function and bronchoalveolar lavage in interstitial lung disease. *Chest* 1989; 96: 1224–1227.
92. Muers MF, Middleton WG, Gibson GJ, et al. A simple radiographic scoring method for monitoring pulmonary sarcoidosis: relations between radiographic scores, dyspnoea grade and respiratory function in the British Thoracic Society Study of Long-Term Corticosteroid Treatment. *Sarcoidosis Vasc Diffuse Lung Dis* 1997; 14: 46–56.
93. Oberstein A, von Zitzewitz H, Schweden F, Muller-Quernheim J. Non invasive evaluation of the inflammatory activity in sarcoidosis with high-resolution computed tomography. *Sarcoidosis Vasc Diffuse Lung Dis* 1997; 14: 65–72.
94. Hansell DM, Milne DG, Wilsher ML, Wells AU. Pulmonary sarcoidosis: morphologic associations of airflow obstruction at thin-section CT. *Radiology* 1998; 209: 697–704.
95. Drent M, De Vries J, Lenters M, et al. Sarcoidosis: assessment of disease severity using HRCT. *Eur Radiol* 2003; 13: 2462–2471.
96. Akira M, Kozuka T, Inoue Y, Sakatani M. Long-term follow-up CT scan evaluation in patients with pulmonary sarcoidosis. *Chest* 2005; 127: 185–191.
97. Finkel R, Teirstein AS, Levine R, Brown LK, Miller A. Pulmonary function tests, serum angiotensin-converting enzyme levels, and clinical findings as prognostic indicators in sarcoidosis. *Ann N Y Acad Sci* 1986; 465: 665–671.
98. Keogh BA, Hunninghake GW, Line BR, Crystal RG. The alveolitis of pulmonary sarcoidosis. Evaluation of natural history and alveolitis-dependent changes in lung function. *Am Rev Respir Dis* 1983; 128: 256–265.
99. Lieberman J, Schleissner LA, Nosal A, Sastre A, Mishkin FS. Clinical correlations of serum angiotensin-converting enzyme (ACE) in sarcoidosis. A longitudinal study of serum ACE, ⁶⁷gallium scans, chest roentgenograms, and pulmonary function. *Chest* 1983; 84: 522–528.
100. Johns CJ, Macgregor MI, Zachary JB, Ball WC. Extended experience in the long-term corticosteroid treatment of pulmonary sarcoidosis. *Ann N Y Acad Sci* 1976; 278: 722–731.
101. Odlum CM, FitzGerald MX. Evidence that steroids alter the natural history of previously untreated progressive pulmonary sarcoidosis. *Sarcoidosis* 1986; 3: 40–46.
102. Bradvik I, Wollmer P, Blom-Bulow B, Albrechtsson U, Jonson B. Lung mechanics and gas

-
- exchange in steroid treated pulmonary sarcoidosis. A seven year follow-up. *Sarcoidosis* 1991; 8: 105–114.
103. Zaki M, Lyons H, Leilop L, Huang C. Corticosteroid therapy in sarcoidosis. A five-year, controlled follow-up study. *NY State J Med* 1987; 87: 496–499.
104. Goldstein DS, Williams MH. Rate of improvement of pulmonary function in sarcoidosis during treatment with corticosteroids. *Thorax* 1986; 41: 473–474.
105. Muller-Quernheim J, Pfeifer S, Strausz J, Ferlinz R. Correlation of clinical and immunologic parameters of the inflammatory activity of pulmonary sarcoidosis. *Am Rev Respir Dis* 1991; 144: 1322–1329.
106. Rothkrantz-Kos S, van Diejen-Visser MP, Mulder PG, Drent M. Potential usefulness of inflammatory markers to monitor respiratory functional impairment in sarcoidosis. *Clin Chem* 2003; 49: 1510–1517.
107. Grutters JC, Fellrath JM, Mulder L, Janssen R, van den Bosch JM, van Velzen-Blad H. Serum soluble interleukin-2 receptor measurement in patients with sarcoidosis: a clinical evaluation. *Chest* 2003; 124: 186–195.
108. Siltzbach LE. The Kveim test in sarcoidosis. A study of 750 patients. *JAMA* 1961; 178: 476–482.
109. Newman LS, Rose CS, Maier LA. Sarcoidosis. *N Engl J Med* 1997; 336: 1224–1234.
110. Robinson BW, McLemore TL, Crystal RG. Gamma interferon is spontaneously released by alveolar macrophages and lung T lymphocytes in patients with pulmonary sarcoidosis. *J Clin Invest* 1985; 75: 1488–1495.
111. Pinkston P, Bitterman PB, Crystal RG. Spontaneous release of interleukin-2 by lung T lymphocytes in active pulmonary sarcoidosis. *N Engl J Med* 1983; 308: 793–800.
112. Drent M, Jacobs JA, Cobben NA, Costabel U, Wouters EF, Mulder PG. Computer program supporting the diagnostic accuracy of cellular BALF analysis: a new release. *Respir Med* 2001; 95: 781–786.
113. Welker L, Jorres RA, Costabel U, Magnussen H. Predictive value of BAL cell differentials in the diagnosis of interstitial lung diseases. *Eur Respir J* 2004; 24: 1000–1006.
114. Drent M, van Velzen-Blad H, Diamant M, Hoogsteden HC, van den Bosch JM. Relationship between presentation of sarcoidosis and T lymphocyte profile. A study in bronchoalveolar lavage fluid. *Chest* 1993; 104: 795–800.
115. Drent M, Mulder PG, Wagenaar S, Hoogsteden HC, van Velzen-Blad H, van den Bosch JM. Differences in BAL fluid variables in interstitial lung diseases evaluated by discriminant analysis. *Eur Respir J* 1993; 6: 803–810.
116. Ziegenhagen MW, Rothe ME, Schlaak M, Muller-Quernheim J. Bronchoalveolar and serological parameters reflecting the severity of sarcoidosis. *Eur Respir J* 2003; 21: 407–413.
117. Drent M, Jacobs JA, De Vries J, Lamers RJ, Liem IH, Wouters EF. Does the cellular bronchoalveolar lavage fluid profile reflect the severity of sarcoidosis? *Eur Respir J* 1999; 13: 1338–1344.
118. Bjermer L, Rosenhall L, Angstrom T, Hallgren R. Predictive value of bronchoalveolar lavage cell analysis in sarcoidosis. *Thorax* 1988; 43: 284–288.
119. Ward K, O'Connor C, Odum C, Fitzgerald MX. Prognostic value of bronchoalveolar lavage in sarcoidosis: the critical influence of disease presentation. *Thorax* 1989; 44: 6–12.
120. Valeyre D, Saumon G, Georges R, *et al.* The relationship between disease duration and noninvasive pulmonary explorations in sarcoidosis with erythema nodosum. *Am Rev Respir Dis* 1984; 129: 938–942.
121. Mañá J. Nuclear imaging. 67Gallium, 201thallium, 18F-labeled fluoro-2-deoxy-D-glucose positron emission tomography. *Clin Chest Med* 1997; 18: 799–811.
122. Schuster DM, Alazraki N. Gallium and other agents in diseases of the lung. *Semin Nucl Med* 2002; 32: 193–211.
123. Kwekkeboom DJ, Krenning EP, Kho GS, Breeman WA, Van Hagen PM. Somatostatin receptor imaging in patients with sarcoidosis. *Eur J Nucl Med* 1998; 25: 1284–1292.
-

-
124. Shorr AF, Helman DL, Lettieri CJ, Montilla JL, Bridwell RS. Depreotide scanning in sarcoidosis: a pilot study. *Chest* 2004; 126: 1337–1343.
 125. El-Haddad G, Zhuang H, Gupta N, Alavi A. Evolving role of positron emission tomography in the management of patients with inflammatory and other benign disorders. *Semin Nucl Med* 2004; 34: 313–329.
 126. Alavi A, Gupta N, Alberini JL, et al. Positron emission tomography imaging in nonmalignant thoracic disorders. *Semin Nucl Med* 2002; 32: 293–321.
 127. Halter G, Buck AK, Schirrmeister H, et al. [18F] 3-deoxy-3'-fluorothymidine positron emission tomography: alternative or diagnostic adjunct to 2-[18F]-fluoro-2-deoxy-D-glucose positron emission tomography in the workup of suspicious central focal lesions? *J Thorac Cardiovasc Surg* 2004; 127: 1093–1099.
 128. Gilman MJ, Wang KP. Transbronchial lung biopsy in sarcoidosis. An approach to determine the optimal number of biopsies. *Am Rev Respir Dis* 1980; 122: 721–724.
 129. Poe RH, Israel RH, Utell MJ, Hall WJ. Probability of a positive transbronchial lung biopsy result in sarcoidosis. *Arch Intern Med* 1979; 139: 761–763.
 130. Wang KP, Fuenning C, Johns CJ, Terry PB. Flexible transbronchial needle aspiration for the diagnosis of sarcoidosis. *Ann Otol Rhinol Laryngol* 1989; 98: Suppl. 4 Pt 1, 298–300.
 131. Leonard C, Tormey V, Lennon A, Burke CM. Utility of Wang transbronchial needle biopsy in sarcoidosis. *Ir J Med Sci* 1997; 166: 41–43.
 132. Cetinkaya E, Yildiz P, Kadakal F, et al. Transbronchial needle aspiration in the diagnosis of intrathoracic lymphadenopathy. *Respiration* 2002; 69: 335–338.
 133. Sharafkhaneh A, Baaklini W, Gorin AB, Green L. Yield of transbronchial needle aspiration in diagnosis of mediastinal lesions. *Chest* 2003; 124: 2131–35.
 134. Trisolini R, Agli LL, Cancellieri A, et al. The value of flexible transbronchial needle aspiration in the diagnosis of stage I sarcoidosis. *Chest* 2003; 124: 2126–2130.
 135. Morales CF, Patefield AJ, Strollo PJ Jr, Schenk DA. Flexible transbronchial needle aspiration in the diagnosis of sarcoidosis. *Chest* 1994; 106: 709–711.
 136. Trisolini R, Lazzari Agli L, Cancellieri A, et al. Transbronchial needle aspiration improves the diagnostic yield of bronchoscopy in sarcoidosis. *Sarcoidosis Vasc Diffuse Lung Dis* 2004; 21: 147–151.
 137. Prakash UB, Offord KP, Stubbs SE. Bronchoscopy in North America: the ACCP survey. *Chest* 1991; 100: 1668–1675.
 138. Tambouret R, Geisinger KR, Powers CN, et al. The clinical application and cost analysis of fine-needle aspiration biopsy in the diagnosis of mass lesions in sarcoidosis. *Chest* 2000; 117: 1004–1011.
 139. Zwischenberger JB, Savage C, Alpard SK, Anderson CM, Marroquin S, Goodacre BW. Mediastinal transthoracic needle and core lymph node biopsy: should it replace mediastinoscopy? *Chest* 2002; 121: 1165–1170.
 140. Pedersen BH, Vilmann P, Folke K, et al. Endoscopic ultrasonography and real-time guided fine-needle aspiration biopsy of solid lesions of the mediastinum suspected of malignancy. *Chest* 1996; 110: 539–544.
 141. Larsen SS, Krasnik M, Vilmann P, et al. Endoscopic ultrasound guided biopsy of mediastinal lesions has a major impact on patient management. *Thorax* 2002; 57: 98–103.
 142. Wiersema MJ, Vazquez-Sequeiros E, Wiersema LM. Evaluation of mediastinal lymphadenopathy with endoscopic US-guided fine-needle aspiration biopsy. *Radiology* 2001; 219: 252–257.
 143. Hammoud ZT, Anderson RC, Meyers BF, et al. The current role of mediastinoscopy in the evaluation of thoracic disease. *J Thorac Cardiovasc Surg* 1999; 118: 894–899.
 144. Kirschner PA. Cervical mediastinoscopy. *Chest Surg Clin N Am* 1996; 6: 1–20.
 145. Venissac N, Alifano M, Mouroux J. Video-assisted mediastinoscopy: experience from 240 consecutive cases. *Ann Thorac Surg* 2003; 76: 208–212.
 146. Blewett CJ, Bennett WF, Miller JD, Urschel JD. Open lung biopsy as an outpatient procedure. *Ann Thorac Surg* 2001; 71: 1113–1115.
-

-
147. Chang AC, Yee J, Orringer MB, Iannettoni MD. Diagnostic thoracoscopic lung biopsy: an outpatient experience. *Ann Thorac Surg* 2002; 74: 1942–6; discussion 1946–1947.
 148. Liebow AA. The J. Burns Amberson lecture--pulmonary angitis and granulomatosis. *Am Rev Respir Dis* 1973; 108: 1–18.
 149. Churg A. Pulmonary angitis and granulomatosis revisited. *Hum Pathol* 1983; 14: 868–883.
 150. Chittock DR, Joseph MG, Paterson NA, McFadden RG. Necrotizing sarcoid granulomatosis with pleural involvement. Clinical and radiographic features. *Chest* 1994; 106: 672–676.
 151. Niimi H, Hartman TE, Muller NL. Necrotizing sarcoid granulomatosis: computed tomography and pathologic findings. *J Comput Assist Tomogr* 1995; 19: 920–923.
 152. Koss MN, Hochholzer L, Feigin DS, Garancis JC, Ward PA. Necrotizing sarcoid-like granulomatosis: clinical, pathologic, and immunopathologic findings. *Hum Pathol* 1980; 11: Suppl. 5, 510–519.
 153. Churg A, Carrington CB, Gupta R. Necrotizing sarcoid granulomatosis. *Chest* 1979; 76: 406–413.
 154. Onal E, Lopata M, Lourenco RV. Nodular pulmonary sarcoidosis. Clinical, roentgenographic, and physiologic course in five patients. *Chest* 1977; 72: 296–300.
 155. Romer FK. Sarcoidosis with large nodular lesions simulating pulmonary metastases. An analysis of 126 cases of intrathoracic sarcoidosis. *Scand J Respir Dis* 1977; 58: 11–16.
 156. Tellis CJ, Putnam JS. Cavitation in large multinodular pulmonary disease a rare manifestation of sarcoidosis. *Chest* 1977; 71: 792–793.
 157. Olsson T, Bjornstad-Pettersen H, Stjernberg NL. Bronchostenosis due to sarcoidosis: a cause of atelectasis and airway obstruction simulating pulmonary neoplasm and chronic obstructive pulmonary disease. *Chest* 1979; 75: 663–666.
 158. Mendelson DS, Norton K, Cohen BA, Brown LK, Rabinowitz JG. Bronchial compression: an unusual manifestation of sarcoidosis. *J Comput Assist Tomogr* 1983; 7: 892–894.
 159. Armstrong JR, Radke JR, Kvale PA, Eichenhorn MS, Popovich J Jr. Endoscopic findings in sarcoidosis. Characteristics and correlations with radiographic staging and bronchial mucosal biopsy yield. *Ann Otol Rhinol Laryngol* 1981; 90: Suppl. 4 Pt 1, 339–343.
 160. Munt PW. Middle lobe atelectasis in sarcoidosis. Report of a case with prompt resolution concomitant with corticosteroid administration. *Am Rev Respir Dis* 1973; 108: 357–360.
 161. Rockoff SD, Rohatgi PK. Unusual manifestations of thoracic sarcoidosis. *Am J Roentgenol* 1985; 144: 513–528.
 162. Aye M, Campbell AP, Greenstone MA. An unusual case of lobar collapse. *Chest* 2002; 122: 1465–1466.
 163. Naidich DP, Lee JJ, Garay SM, McCauley DI, Aranda CP, Boyd AD. Comparison of CT and fiberoptic bronchoscopy in the evaluation of bronchial disease. *Am J Roentgenol* 1987; 148: 1–7.
 164. Fouty BW, Pomeranz M, Thigpen TP, Martin RJ. Dilatation of bronchial stenoses due to sarcoidosis using a flexible fiberoptic bronchoscope. *Chest* 1994; 106: 677–680.
 165. Tomlinson JR, Sahn SA. Aspergilloma in sarcoid and tuberculosis. *Chest* 1987; 92: 505–508.
 166. Wollschlager C, Khan F. Aspergillomas complicating sarcoidosis. A prospective study in 100 patients. *Chest* 1984; 86: 585–588.
 167. Israel HL, Lenchner GS, Atkinson GW. Sarcoidosis and aspergilloma. The role of surgery. *Chest* 1982; 82: 430–432.
 168. Libshitz HI, Atkinson GW, Israel HL. Pleural thickening as a manifestation of aspergillus superinfection. *Am J Roentgenol Radium Ther Nucl Med* 1974; 120: 883–886.
 169. Fujimura M, Ishiura Y, Kasahara K, et al. Necrotizing bronchial aspergillosis as a cause of hemoptysis in sarcoidosis. *Am J Med Sci* 1998; 315: 56–58.
 170. Shapiro MJ, Albelda SM, Mayock RL, McLean GK. Severe hemoptysis associated with pulmonary aspergilloma. Percutaneous intracavitary treatment. *Chest* 1988; 94: 1225–1231.
 171. Rumbak M, Kohler G, Eastrige C, Winer-Muram H, Gavant M. Topical treatment of life threatening haemoptysis from aspergillomas. *Thorax* 1996; 51: 253–255.
-

-
172. Nicholls AJ, Friend JA, Legge JS. Sarcoid pleural effusion: three cases and review of the literature. *Thorax* 1980; 35: 277–281.
 173. Soskel N, Sharma OP. Pleural involvement in sarcoidosis. Case presentation and detailed review of the literature. *Semin Resp Med* 1992; 13: 492–514.
 174. Warshawsky ME, Shanies HM, Roza A. Sarcoidosis involving the thyroid and pleura. *Sarcoidosis Vasc Diffuse Lung Dis* 1997; 14: 165–168.
 175. Aberg H, Bah M, Waters AW. Sarcoidosis: complicated by chylothorax. *Minn Med* 1966; 49: 1065–1070.
 176. Cappell MS, Friedman D, Mikhail N. Chyloperitoneum associated with chronic severe sarcoidosis. *Am J Gastroenterol* 1993; 88: 99–101.
 177. Jarman PR, Whyte MK, Sabroe I, Hughes JM. Sarcoidosis presenting with chylothorax. *Thorax* 1995; 50: 1324–1325.
 178. Rosen Y, Moon S, Huang CT, Gourin A, Lyons HA. Granulomatous pulmonary angiitis in sarcoidosis. *Arch Pathol Lab Med* 1977; 101: 170–174.
 179. Smith LJ, Lawrence JB, Katzenstein AA. Vascular sarcoidosis: a rare cause of pulmonary hypertension. *Am J Med Sci* 1983; 285: 38–44.
 180. Barst RJ, Ratner SJ. Sarcoidosis and reactive pulmonary hypertension. *Arch Intern Med* 1985; 145: 2112–2114.
 181. Gluskowski J, Hawrylkiewicz I, Zych D, Zielinski J. Effects of corticosteroid treatment on pulmonary haemodynamics in patients with sarcoidosis. *Eur Respir J* 1990; 3: 403–407.
 182. Battesti JP, Georges R, Basset F, Saumon G. Chronic cor pulmonale in pulmonary sarcoidosis. *Thorax* 1978; 33: 76–84.
 183. Emirgil C, Sobol BJ, Herbert WH, Trout K. The lesser circulation in pulmonary fibrosis secondary to sarcoidosis and its relationship to respiratory function. *Chest* 1971; 60: 371–378.
 184. Gluskowski J, Hawrylkiewicz I, Zych D, Wojtczak A, Zielinski J. Pulmonary haemodynamics at rest and during exercise in patients with sarcoidosis. *Respiration* 1984; 46: 26–32.
 185. Arcasoy SM, Christie JD, Pochettino A, *et al.* Characteristics and outcomes of patients with sarcoidosis listed for lung transplantation. *Chest* 2001; 120: 873–880.
 186. Shorr AF, Davies DB, Nathan SD. Outcomes for patients with sarcoidosis awaiting lung transplantation. *Chest* 2002; 122: 233–238.
 187. Shorr AF, Davies DB, Nathan SD. Predicting mortality in patients with sarcoidosis awaiting lung transplantation. *Chest* 2003; 124: 922–928.
 188. Preston IR, Klinger JR, Landzberg MJ, Houtchens J, Nelson D, Hill NS. Vasoresponsiveness of sarcoidosis-associated pulmonary hypertension. *Chest* 2001; 120: 866–872.
 189. Tan RT, Kuzo R, Goodman LR, Siegel R, Haasler GB, Presberg KW. Utility of CT scan evaluation for predicting pulmonary hypertension in patients with parenchymal lung disease. Medical College of Wisconsin Lung Transplant Group. *Chest* 1998; 113: 1250–1256.
 190. Ng CS, Wells AU, Padley SP. A CT sign of chronic pulmonary arterial hypertension: the ratio of main pulmonary artery to aortic diameter. *J Thorac Imaging* 1999; 14: 270–278.
 191. Jones K, Higenbottam T, Wallwork J. Pulmonary vasodilation with prostacyclin in primary and secondary pulmonary hypertension. *Chest* 1989; 96: 784–789.
 192. Damuth TE, Bower JS, Cho K, Dantzker DR. Major pulmonary artery stenosis causing pulmonary hypertension in sarcoidosis. *Chest* 1980; 78: 888–891.
 193. Hamper UM, Fishman EK, Khouri NF, Johns CJ, Wang KP, Siegelman SS. Typical and atypical CT manifestations of pulmonary sarcoidosis. *J Comput Assist Tomogr* 1986; 10: 928–936.
 194. Hietala SO, Stinnett RG, Faunce HF 3rd, Sharpe AR Jr, Scoggins WG, Smith RH. Pulmonary artery narrowing in sarcoidosis. *JAMA* 1977; 237: 572–573.
 195. Westcott JL, DeGraff AC Jr. Sarcoidosis, hilar adenopathy, and pulmonary artery narrowing. *Radiology* 1973; 108: 585–586.
 196. Hoffstein V, Ranganathan N, Mullen JB. Sarcoidosis simulating pulmonary veno-occlusive disease. *Am Rev Respir Dis* 1986; 134: 809–811.
-

-
197. Schachter EN, Smith GJ, Cohen GS, Lee SH, Laser A, Gee JB. Pulmonary granulomas in a patient with pulmonary veno-occlusive disease. *Chest* 1975; 67: 487–489.
 198. Javaheri S, Hales CA. Sarcoidosis: a cause of innominate vein obstruction and massive pleural effusion. *Lung* 1980; 157: 81–85.
 199. Gordonson J, Trachtenberg S, Sargent EN. Superior vena cava obstruction due to sarcoidosis. *Chest* 1973; 63: 292–293.
 200. Westcott JL, Noehren TH. Bronchial stenosis in chronic sarcoidosis. *Chest* 1973; 63: 893–897.
 201. Brandstetter RD, Hansen DE, Jarowski CI, King T, Barletta A. Superior vena cava syndrome as the initial clinical manifestation of sarcoidosis. *Heart Lung* 1981; 10: 101–104.
 202. Radke JR, Kaplan H, Conway WA. The significance of superior vena cava syndrome developing in a patient with sarcoidosis. *Radiology* 1980; 134: 311–312.
 203. Kinney EL, Murthy R, Ascunce G, Guntapalli KK, Zelis R. Sarcoidosis: rare cause of superior vena caval obstruction. *Pa Med* 1980; 83: 31.
 204. Case records of the Massachusetts General Hospital. Weekly clinicopathological exercises. Case 11-1984. Long-standing sarcoidosis with the recent onset of the superior-vena-cava syndrome. *N Engl J Med* 1984; 310: 708–716.
 205. Hasday JD, Bachwich PR, Lynch JP 3rd, Sitrin RG. Procoagulant and plasminogen activator activities of bronchoalveolar fluid in patients with pulmonary sarcoidosis. *Exp Lung Res* 1988; 14: 261–278.
 206. Chapelon-Abrie C, Evrard S, Buthiau D, Wechsler B, Bousser MG. [Cerebral thrombophlebitis in sarcoidosis]. *Rev Med Interne* 1994; 15: 216–217.
 207. Raheison C, Nocent C, Tunon De Lara JM, Latrabe V, Laurent F, Taytard A. [Mediastinal sarcoidosis and vascular thrombosis: a fortuitous association?]. *Rev Mal Respir* 2001; 18: 63–65.
 208. Morello FA, Ali SA, Cesani F. Sarcoid: an unusual mimicker of classic pulmonary embolus. *Clin Nucl Med* 1998; 23: 654–656.
 209. Finestone H, Colp C, Rackson M, Shams J, Gallagher R. Ventilation-perfusion imaging in sarcoidosis: potential for nonembolic segmental mismatch. *J Nucl Med* 1994; 35: 476–478.
 210. Velchik MG, Tobin M, McCarthy K. Nonthromboembolic causes of high-probability lung scans. *Am J Physiol Imaging* 1989; 4: 32–38.
 211. Cassling RJ, Lois JF, Gomes AS. Unusual pulmonary angiographic findings in suspected pulmonary embolism. *Am J Roentgenol* 1985; 145: 995–999.
 212. Stanley DC, Cho SR, Tisnado J, Vines FS, Coyne SS. Pulmonary arteriography in patients with hilar or mediastinal masses and lung scans suggesting pulmonary embolism. *South Med J* 1981; 74: 960–964, 967.
 213. Shorr AF, Hnatiuk OW. Circulating D dimer in patients with sarcoidosis. *Chest* 2000; 117: 1012–1016.
 214. Haramati LB, Lee G, Singh A, Molina PL, White CS. Newly diagnosed pulmonary sarcoidosis in HIV-infected patients. *Radiology* 2001; 218: 242–246.
 215. Newman TG, Minkowitz S, Hanna A, Sikand R, Fuleihan F. Coexistent sarcoidosis and HIV infection. A comparison of bronchoalveolar and peripheral blood lymphocytes. *Chest* 1992; 102: 1899–1901.
 216. Gomez V, Smith PR, Burack J, Daley R, Rosa U. Sarcoidosis after antiretroviral therapy in a patient with acquired immunodeficiency syndrome. *Clin Infect Dis* 2000; 31: 1278–1280.
 217. Foulon G, Wislez M, Naccache JM, et al. Sarcoidosis in HIV-infected patients in the era of highly active antiretroviral therapy. *Clin Infect Dis* 2004; 38: 418–425.
 218. Naccache JM, Antoine M, Wislez M, et al. Sarcoid-like pulmonary disorder in human immunodeficiency virus-infected patients receiving antiretroviral therapy. *Am J Respir Crit Care Med* 1999; 159: 2009–2013.
 219. Mirmirani P, Maurer TA, Herndier B, McGrath M, Weinstein MD, Berger TG. Sarcoidosis in a patient with AIDS: a manifestation of immune restoration syndrome. *J Am Acad Dermatol* 1999; 41: Suppl. 2 Pt 2, 285–286.
-

-
220. Lenner R, Bregman Z, Teirstein AS, DePalo L. Recurrent pulmonary sarcoidosis in HIV-infected patients receiving highly active antiretroviral therapy. *Chest* 2001; 119: 978–981.
 221. Granieri J, Wisnieski JJ, Graham RC, Smith H, Gogate P, Aucott JN. Sarcoid myopathy in a patient with human immunodeficiency virus infection. *South Med J* 1995; 88: 591–595.
 222. Mayaud CM, Cadranet J. HIV in the lung: guilty or not guilty? *Thorax* 1993; 48: 1191–1195.
 223. Morris DG, Jasmer RM, Huang L, Gotway MB, Nishimura S, King TE Jr. Sarcoidosis following HIV infection: evidence for CD4+ lymphocyte dependence. *Chest* 2003; 124: 929–935.
 224. Charlier C, Nunes H, Trinchet JC, et al. Evolution of previous sarcoidosis under type I interferons given for severe associated disease. *Eur Respir J* 2005; 25: 570–573.
 225. Leclerc S, Myers RP, Moussalli J, Herson S, Poynard T, Benveniste O. Sarcoidosis and interferon therapy: report of five cases and review of the literature. *Eur J Intern Med* 2003; 14: 237–243.
 226. Menon Y, Cucurull E, Reisin E, Espinoza LR. Interferon-alpha-associated sarcoidosis responsive to infliximab therapy. *Am J Med Sci* 2004; 328: 173–175.
 227. Ravenel JG, McAdams HP, Plankeel JF, Butnor KJ, Sporn TA. Sarcoidosis induced by interferon therapy. *Am J Roentgenol* 2001; 177: 199–201.
 228. Pietropaoli A, Modrak J, Utell M. Interferon-alpha therapy associated with the development of sarcoidosis. *Chest* 1999; 116: 569–572.
 229. Rubinowitz AN, Naidich DP, Alinsonorin C. Interferon-induced sarcoidosis. *J Comput Assist Tomogr* 2003; 27: 279–283.
 230. Husa P, Klusakova J, Jancikova J, Husova L, Horalek F. Sarcoidosis associated with interferon-alpha therapy for chronic hepatitis B. *Eur J Intern Med* 2002; 13: 129–131.
 231. Nawras A, Alsolaiman MM, Mehboob S, Bartholomew C, Maliakkal B. Systemic sarcoidosis presenting as a granulomatous tattoo reaction secondary to interferon-alpha treatment for chronic hepatitis C and review of the literature. *Dig Dis Sci* 2002; 47: 1627–1631.
 232. Baughman RP, Sharma OP, Lynch JP 3rd. Sarcoidosis: is therapy effective? *Semin Respir Infect* 1998; 13: 255–273.
 233. Johns CJ, Schonfeld SA, Scott PP, Zachary JB, MacGregor MI. Longitudinal study of chronic sarcoidosis with low-dose maintenance corticosteroid therapy. Outcome and complications. *Ann N Y Acad Sci* 1986; 465: 702–712.
 234. Eule H, Weinecke A, Roth I, Wuthe H. The possible influence of corticosteroid therapy on the natural course of pulmonary sarcoidosis. Late results of a continuing clinical study. *Ann N Y Acad Sci* 1986; 465: 695–701.
 235. Young RL, Harkleroad LE, Lordon RE, Weg JG. Pulmonary sarcoidosis: a prospective evaluation of glucocorticoid therapy. *Ann Intern Med* 1970; 73: 207–212.
 236. Israel HL, Fouts DW, Beggs RA. A controlled trial of prednisone treatment of sarcoidosis. *Am Rev Respir Dis* 1973; 107: 609–614.
 237. Yamamoto M, Saito N, Tachibana T. Effects of an 18 month corticosteroid therapy to stage I and stage II sarcoidosis patients (control trial). In: Chretien J, Marsac J, Saltiel JC, eds. Sarcoidosis and other granulomatous disorders. Paris, Pergamon Press, 1980; pp. 470–474.
 238. Selroos O, Sellergren T. Corticosteroid therapy of pulmonary sarcoidosis. A prospective evaluation of alternate day and daily dosage in stage II disease. *Scand J Respir Dis* 1979; 60: 215–221.
 239. O’Leary TJ, Jones G, Yip A, Lohnes D, Cohanin M, Yendt ER. The effects of chloroquine on serum 1,25-dihydroxyvitamin D and calcium metabolism in sarcoidosis. *N Engl J Med* 1986; 315: 727–730.
 240. Muller-Quernheim J, Kienast K, Held M, Pfeifer S, Costabel U. Treatment of chronic sarcoidosis with an azathioprine/prednisolone regimen. *Eur Respir J* 1999; 14: 1117–1122.
 241. Lewis SJ, Ainslie GM, Bateman ED. Efficacy of azathioprine as second-line treatment in pulmonary sarcoidosis. *Sarcoidosis Vasc Diffuse Lung Dis* 1999; 16: 87–92.
 242. Baltzan M, Mehta S, Kirkham TH, Cosio MG. Randomized trial of prolonged chloroquine therapy in advanced pulmonary sarcoidosis. *Am J Respir Crit Care Med* 1999; 160: 192–197.
-

-
243. Baughman RP, Lower EE. Infliximab for refractory sarcoidosis. *Sarcoidosis Vasc Diffuse Lung Dis* 2001; 18: 70–74.
 244. Utz JP, Limper AH, Kalra S, *et al.* Etanercept for the treatment of stage II and III progressive pulmonary sarcoidosis. *Chest* 2003; 124: 177–185.
 245. Baughman RP, Lower EE. Leflunomide for chronic sarcoidosis. *Sarcoidosis Vasc Diffuse Lung Dis* 2004; 21: 43–48.
 246. Trulock EP, Edwards LB, Taylor DO, Boucek MM, Keck BM, Hertz MI. The registry of the International Society for Heart and Lung Transplantation: twenty-first official adult heart transplant report—2004. *J Heart Lung Transplant* 2004; 23: 804–815.
 247. Shorr AF, Helman DL, Davies DB, Nathan SD. Sarcoidosis, race, and short-term outcomes following lung transplantation. *Chest* 2004; 125: 990–996.
 248. Young CJ, Gaston RS. African Americans and renal transplantation: disproportionate need, limited access, and impaired outcomes. *Am J Med Sci* 2002; 323: 94–99.
 249. Nair S, Eustace J, Thuluvath PJ. Effect of race on outcome of orthotopic liver transplantation: a cohort study. *Lancet* 2002; 359: 287–293.
 250. Nunley DR, Hattler B, Keenan RJ, *et al.* Lung transplantation for end-stage pulmonary sarcoidosis. *Sarcoidosis Vasc Diffuse Lung Dis* 1999; 16: 93–100.
 251. Walker S, Mikhail G, Banner N, *et al.* Medium term results of lung transplantation for end stage pulmonary sarcoidosis. *Thorax* 1998; 53: 281–284.
 252. Collins J, Hartman MJ, Warner TF, *et al.* Frequency and CT findings of recurrent disease after lung transplantation. *Radiology* 2001; 219: 503–509.
 253. Hadjiliadis D, Sporn PA, Perfect JR, Tapson VF, Davis RD, Palmer SM. Outcome of lung transplantation in patients with mycetomas. *Chest* 2002; 121: 128–134.