

Generalized sarcoidosis in two horses

E.P.R. Reijkerk¹, E.J.B.Veldhuis Kroeze^{II} and M.M. Sloet van Oldruitenborgh-Oosterbaan¹

.....

Tijdschr Diergeneeskd 2008; 133: 654-661

Oorspronkelijk artikel

SUMMARY

Equine sarcoidosis is a rare disorder usually characterized by exfoliative dermatitis, moderate to severe wasting, and sarcoidal granulomatous inflammation of multiple organ systems. It has an unknown aetiopathogenesis. The condition is not related to equine sarcoid. This case report describes generalized cutaneous and systemic sarcoidosis in an 11-year-old Trakehner mare (case A) and in a 7-year-old Dutch Warmblood gelding (case B).

Case A was presented with cutaneous sarcoidosis on the head and body and was diagnosed on the basis of histological examination of skin. Case B presented with multiple subcutaneous nodules (2-15 cm in diameter) and the diagnosis was established at postmortem examination. Both horses showed distinctive histology of the skin with extensive lymphohistiocytic infiltration and Langhans-type multinucleated giant cells. Haematology and biochemistry revealed a normal total white blood cell count with a right shift in both horses. Case B was anaemic and had a slightly elevated total protein concentration with hyperglobulinaemia. Both horses were unresponsive to corticosteroids and were euthanized.

SAMENVATTING

Gegeneraliseerde sarcoidose bij twee paarden

Equine sarcoidose is een zeldzaam voorkomende aandoening die wordt gekenmerkt door exfoliatieve dermatitis en granulomateuze infiltratie van meerdere orgaansystemen en/of organen. Equine sarcoidose en equine sarcoid zijn twee geheel verschillende ziektebeelden. Equine sarcoidose heeft een onbekende etiologie en pathogenese. Deze casusbespreking beschrijft twee casus met gegeneraliseerde cutane en systemische sarcoidose, een elfjaar oude Trakehner merrie (casus A) en een zeven jaar oude KWPN-ruin (casus B).

Casus A toonde eerst de klinische verschijnselen van cutane sarcoidose op het hoofd en het lichaam en de diagnose werd gesteld op basis van een huidbiopt. Casus B begon met subcutane nodula (2 tot 15 centimeter diameter) en vertoonde pas later de typische huidveranderingen. De diagnose bij dit paard werd gesteld bij postmortaal onderzoek.

Beide paarden toonden bij histologisch onderzoek van de

afwijkende huid de typische veranderingen: uitgebreide lymfohistiocyttaire infiltratie en veel meerkernige reuscellen van het Langhans-type.

Bij bloedonderzoek werd bij beide patiënten een normaal aantal witte bloedcellen met een rechtsverschuiving gevonden. Casus B had ook een anemie en een iets hoge totaal-eiwitconcentratie met een duidelijk verhoogde beta- en gammafractie. Beide paarden reageerden in het verloop van de aandoening onvoldoende of niet op behandeling met systemische corticosteroiden en beide paarden werden op verzoek van de eigenaar geëuthanaseerd.

INTRODUCTION

Equine sarcoidosis, also known as 'equine idiopathic systemic granulomatous disease' (14), 'generalized granulomatous disease' (11), 'systemic granulomatous disease' (17), 'equine histiocytic disease' (11), and 'equine histiocytic dermatitis' (3), is a rare disease of unknown aetiopathogenesis (13). Although the name is similar, the condition is not related to equine cutaneous sarcoid (9). Sarcoidosis also has been reported in humans and cattle (2, 6, 12, 14), based on histopathological findings. The clinical manifestations are quite different in the different species.

Equine sarcoidosis is suggested to be the result of an exaggerated immunological response, with exogenous infectious agent(s) or allergens as the antigenic stimulus (8, 16). No (infectious) agent has been identified as yet (13, 16), and no breed, sex, or age predilection has been established (9, 11, 13, 15, 16). The disease is characterized by exfoliative dermatitis, severe wasting, and granulomatous inflammation of one or more internal organs (9, 13, 16). The skin, lungs, lymph nodes, and gastrointestinal tract are most commonly affected (1, 5, 11, 13, 16). Less commonly affected organs or tissue(s) are the liver, spleen, kidneys, skeletal system, heart, adrenal- and thyroid glands, pancreas, and nervous system (13, 16).

Stannard (17) classified equine sarcoidosis in two forms: the cutaneous form and the nodular form. The most commonly occurring cutaneous form starts clinically with skin lesions, with generalized scaling and crusting combined with variable alopecia of the face and limbs, often with sparing of the mane and the tail (9, 13). The nodular form, with nodules or tumour-like masses, is less common and is often combined with extensive scaling and crusting (11). Recently, a third form, the 'localized form', has been described (13, 15). In these patients the typical hyperkeratotic, crusted, and alopecic areas remain localized (for many years) and occur most often on the lower limbs, and occasionally elsewhere, in otherwise systemically healthy horses that are mostly performing well (15). Non-cutaneous clinical signs, such as a persistent low-grade fever, poor appetite, and decreased performance, are described in horses with systemic sarcoidosis (9, 13, 16). Peripheral lymphadenopathy and variable organ signs may also be detected (9, 11, 16). The presence of mediastinal and pulmonary masses may account for the

¹ Department of Equine Sciences, Faculty of Veterinary Medicine, Utrecht University, Yalelaan 114, 3584 CM Utrecht, the Netherlands.

^{II} Department of Pathobiology, Faculty of Veterinary Medicine, Utrecht University, Yalelaan 1, 3584 CL Utrecht, the Netherlands.

Corresponding author: e.p.r.reijkerk@uu.nl

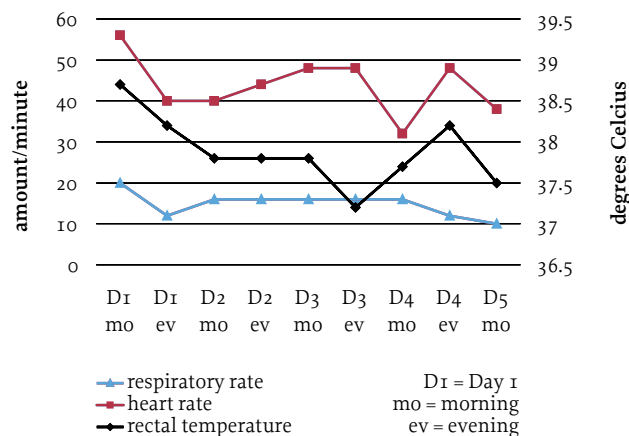


Figure 1. Respiratory rate, heart rate, and rectal temperature of case A during 5 days' hospitalization before euthanasia.

characteristic poor performance and dyspnoea (9), whereas liver and gastrointestinal involvement may account for clinical signs such as icterus and diarrhoea (9). Other organs are rarely involved.

Horses with localized sarcoidosis have no clinical systemic signs other than the affected skin on mostly the lower limb(s), which can become crusty, thick and painful, sometimes resulting in lameness (15). In contrast to most other lower limb dermatoses, sarcoidosis involves both pigmented and unpigmented skin. Pruritus has been reported as a clinical sign in human sarcoidosis and is also reported as a minor presenting sign in some horses (4, 15).

The diagnosis of sarcoidosis is based on clinical and histological findings combined with exclusion of other diseases. Differential diagnoses include dermatophilosis, dermatophytosis, immune-mediated diseases (e.g., pemphigus foliaceus, systemic lupus erythematosus, exfoliative eosinophilic dermatitis, erythema multiforme, food allergies, drug eruptions, and multisystemic eosinophilic epitheliotrophic disease), seborrhoea, verrucous sarcoids, and toxicoses (hairy vetch, arsenic, iodine, aluminium, and silicon) (9, 13, 16). Biopsy of the skin lesions is essential for confirmation of the diagnosis. Typical histopathological lesions include perifollicular and mid- or superficial dermal granulomata, a multifocal nodular to diffuse non-caseating granulomatous dermatitis with histiocytes, multinucleated giant cells, and limited lymphocytic infiltration (9, 13). The clinical management of generalized or localized sarcoidosis is often problematic (11). A few horses show spontaneous remission for no apparent reason (9, 12, 16), but horses with the localized form in particular may show a good response to long courses of systemic corticosteroids (e.g., dexamethasone or prednisolone) (15, 16).

This case report provides the first description of two cases of generalized equine sarcoidosis in the Netherlands.

History

An 11-year-old Trakehner mare was referred to the Department of Equine Sciences at Utrecht University with



2a



2b

Figure 2. An 11-year-old Trakehner mare with generalized scaling and crusting on head, neck, and body resulting from sarcoidosis.

a 4-month history of a skin problem on the head, neck, abdomen, and around the tail and perineum. The horse also showed a slight localized oedematous reaction on the back and abdomen. When the skin problem started, the horse had a raised rectal temperature. The horse was treated with povidone iodine shampoo ^a, seborrhoea shampoo ^b, and insect repellents and was clothed while at pasture with an insect blanket. Later the horse became lethargic and lost its appetite. A few days before referral, the horse coughed occasionally. The mare had a history of recurrent colic and had been operated on for right dorsal displacement 6 months before the onset of the dermatological problem. One month before the skin problem started, the mare had shown signs of 'bronchitis'. These symptoms disappeared after treatment with clenbuterol ^c, prednisolone ^d, and acetylcysteine ^e. Antibiotic treatment resolved the horse's lameness but did not improve the skin

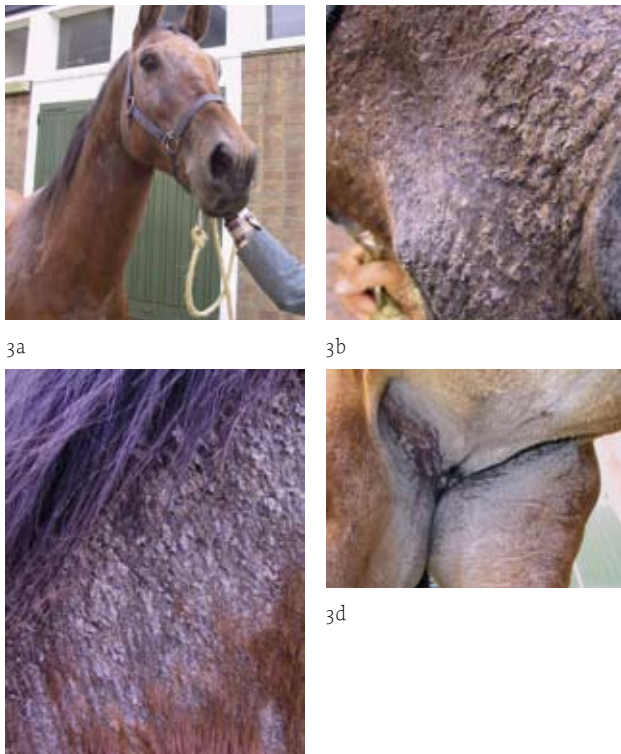a Betadine Shampoo®, Mundipharma, Basel, Switzerland.

b Sebomild P®, Virbac Nederland BV, Barneveld, The Netherlands.

c Ventipulmin®, Boehringer Ingelheim, Alkmaar, The Netherlands.

d Prednisolon®, Alfasan, Woerden, The Netherlands.

e Lysox®, Florence, Italy.



3c

Figure 3. Detailed views of the head (a), mouth (b), neck (c) and udder region (d) of an 11-year-old Trakehner mare with generalized scaling and crusting resulting from sarcoidosis.

problem. One month before referral, consultation with the last author (MS) had led to a tentative diagnosis of immune-mediated skin disease, possibly some form of pemphigus foliaceus, which has a guarded prognosis.

The horse was treated with dexamethasone^f (single dose of 0.08, 0.04, 0.02 and 0.01 mg/kg i.m. for 5, 3, 3 and 3 days, respectively, always in the morning between 07.00 and 09.00 hours). This treatment resulted in an almost complete recovery from the problem; however, the problem returned within a few days after cessation of treatment, and a second course of dexamethasone was less effective. The symptoms deteriorated and the horse was referred to the Department of Equine Sciences for further evaluation.

Clinical findings

On presentation, the mare was alert and in good bodily condition. She had a slightly increased respiratory rate (20 breaths/minute), a slightly elevated heart rate (56 beats/minute), and an increased rectal temperature (38.7°C). The heart rate and rectal temperature were occasionally slightly above reference values over the next 4 days (figure 1). Severe non-painful scaling and some alopecia were found over the entire body (figures 2 and 3). Appetite and faeces production were normal.

Further investigations

Haematological and biochemistry examinations revealed a normal packed cell volume (PCV) and a normal white

Blood variable	Horse A	Horse B	Reference values
PCV (l/l)	0.37	0.26	0.32-0.42
WBC (10 ⁹ /l)	8.2	9.7	7-10
lymphocytic (%)	13	14	30-35
segmented gran (%)	78	84	35-60
band gran (%)	0	0	< 5
eosinophilic (%)	3	0	< 4
basophilic (%)	3	0	< 10
monocytic (%)	3	2	< 5
total protein (g/l)	64	78	60-75
albumin (%)	64.0	35.9	35-55
alpha glob (%)	10.0	15.4	15-20
beta glob (%)	13.6	24.7	< 22
gamma glob (g/l)	12.4	23.1	< 25
urea (mmol/l)	5.3	5.0	< 8 mmol/l
ASAT (IU/l)	104	nd	125-275
LDH (IU/l)	408	nd	240-600
gammaGT (IU/l)	12	nd	< 20
AF (IU/l)	300	nd	180-380
bilir. total (mmol/l)	49.6	nd	< 35
bilir. direct (mmol/l)	2.8	nd	< 25% of total
bilir. indirect (mmol/l)	46.8	nd	> 75% of total

Table 1. Blood haematology and biochemistry of two patients with generalized sarcoidosis.

blood cell count (WBC) with a slight right shift (table 1). Total protein concentration, electrophoresis, and liver enzyme concentrations were within reference values, while the total bilirubin concentration was slightly increased (table 1). Bacteriological examination of a skin scraping revealed no abnormal bacterial growth. Mycological culture of a hair sample was also negative.

Histopathological examination of skin biopsies of the neck and the abdomen revealed crusting, focal neutrophilic exocytosis in the epidermis with some spongiosis. In the upper dermis, diffuse lymphohistiocytic inflammation was visible with some neutrophils, several multinucleated giant cells (figure 4), and localized small granuloma. The pathological diagnosis was generalized equine sarcoidosis.

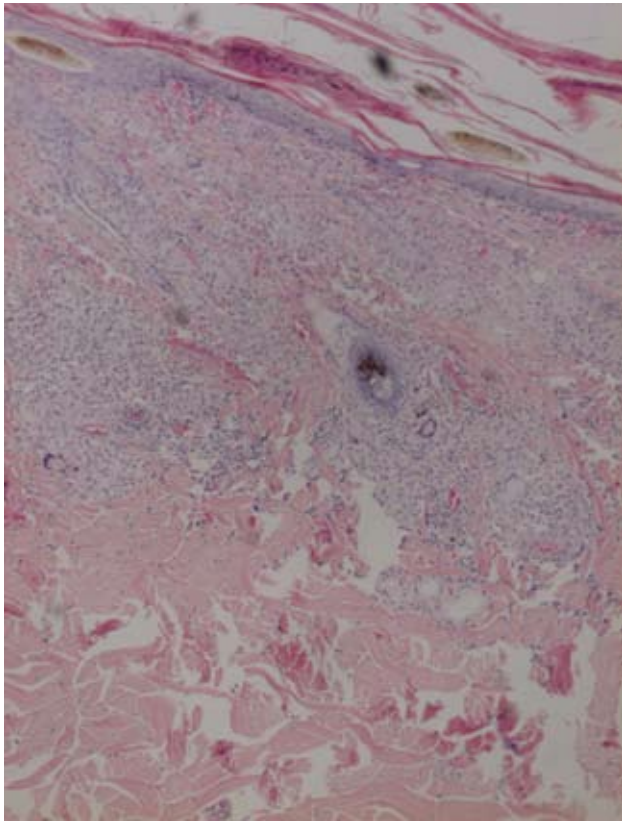
Diagnosis and treatment

Considering the progressive worsening of the clinical symptoms, the limited effect of corticosteroid treatment, and the poor prognosis reported in the literature, the owner and her insurance company opted for euthanasia.

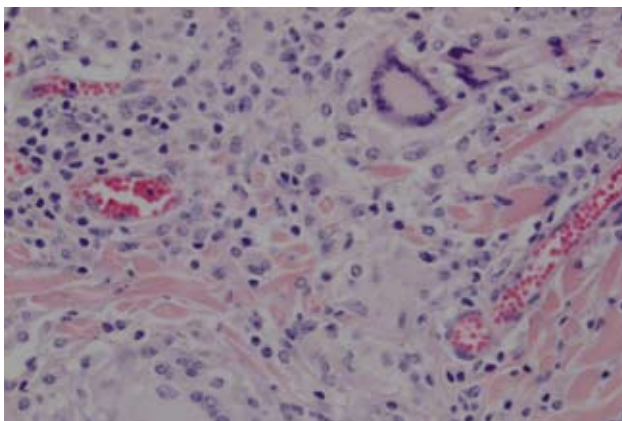
Postmortem examination

Apart from the skin lesions, the only remarkable macroscopic lesions were firm and severely swollen bronchial lymph nodes (figure 5). Microscopic lesions were found in the skin and within the adjacent subcutis and striated muscle. Extensive involvement of the bronchial lymph nodes was present, and multifocal similar nodules were found in the liver. All showed lymphohistiocytic inflammatory infiltrates admixed with large multinucleated giant cells of the Langhans type. These findings were consistent with a diagnosis of generalized sarcoidosis. Other histological evaluated organs were the colon ascendens, spleen, and kidneys; these were unremarkable.

^f Dexadreson®, Intervet Nederland, Boxmeer, The Netherlands.



4a



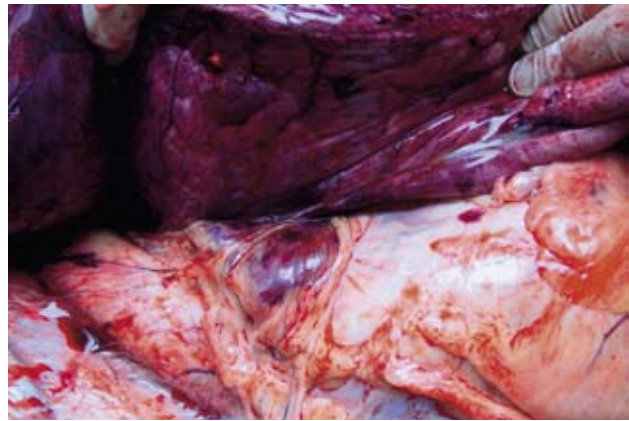4b

Figure 4. Equine sarcoidosis, overview of a biopsy of haired skin with superficial hyperkeratosis and a moderately cellular lymphohistiocytic inflammatory infiltrate within the superficial dermis admixed with several typical multinucleated giant cells (a). Higher magnification (b) shows two typical giant cells of the Langhans type (on top right and bottom left) with abundant pale eosinophilic cytoplasm and a rim of peripheral nuclei (haematoxylin-eosin stain).

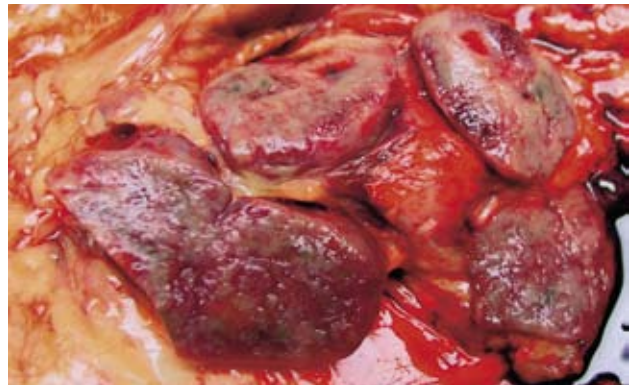
CASE B

History

A 7-year-old Dutch Warmblood gelding was referred to the Department of Equine Sciences at Utrecht University with a one month history of problems that had started a week after rhinopneumonitis vaccination in the right pectoral muscle. After one week, the pectoral region showed a large firm swelling and within a few days subcutaneous nodules were seen on the neck, the back, and the abdomen. The horse subsequently became lethargic and started cough-



5a



5b

Figure 5. At postmortem examination of case A, except the skin, the only macroscopic signs of granulomatous disease noticed were severely swollen and firm bronchial lymph nodes, as seen in the centre of photograph 5a revealed by the partly lifted lung lobe, and on cut sections (5b).

ing. A single dose of dexamethasone g (0.02 mg/kg bodyweight, intramuscular) was not beneficial.

Ultrasonographic examination of the pectoral region performed in practice revealed a 4-cm diameter encapsulated hyperechogenic region. The other nodules were hardly visible on ultrasonographic examination. Fine-needle aspiration biopsy of the pectoral swelling revealed a bloody aspirate with many neutrophilic granulocytes and mesenchymal cells and no evidence of malignant neoplastic disease. Because the horse's performance as a riding-school horse decreased, the horse was referred for further evaluation to the Department of Equine Sciences.

Clinical findings at the University Clinic

On presentation, the horse was alert, in good bodily condition, and showed a slightly increased respiratory rate (20 breaths per minute) and a normal heart rate (36 beats per minute). The rectal temperature was marginally elevated (38.3°C), which may have been the result of transport. Except for the nodules, clinical examination was unremarkable including the lung auscultation. The nodules were localized to the neck, pectoral region, back (saddle region), and abdomen (figure 6). The firm circumscribed swellings varied in diameter from 5 to 15 cm and

g Voreen[®] suspensie, Boehringer Ingelheim, Alkmaar, The Netherlands.

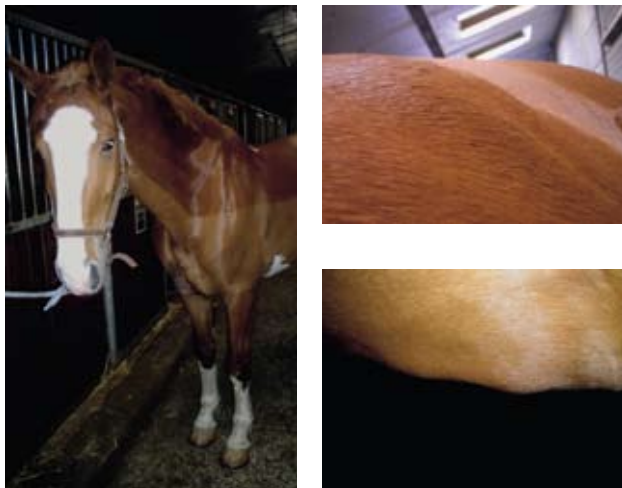


Figure 6. Seven-year-old Dutch Warmblood gelding (case B) with several firm not painful nodules varying in diameter between 5 and 15 cm between the forelimbs, on the neck, in the lumbar region, and on the abdomen.

were covered with a normal skin showing no alopecia, crusting, and/or scaling. All nodules seemed to be located subdermally, with the exception of the large nodule in the right pectoral muscle.

Further investigations

Haematology and biochemistry revealed moderate anaemia and a slightly raised total protein concentration with increased β - and γ -globulin fractions (table 1).

Diagnosis and treatment

The tentative diagnosis was an immune-mediated reaction of unknown origin and prolonged corticosteroid treatment (prednisolone 1 mg/kg per os s.i.d) was advised. After the horse was discharged, there was some improvement and the horse was used again in the riding school. However, the nodules never completely resolved. One month after the end of prednisolone treatment, the nodules were even more prominent than before.

Seven weeks after the horse returned home, the swelling in the pectoral region also enlarged. Findings of repeated ultrasonographic examination of the pectoral region raised suspicion about the development of chronic purulent inflammation, and treatment with laurel ointment^h was started. The appearance of the overlying skin changed, and alopecia and severe crusting and scaling were noticed (figure 7). The nodules all over the body also increased in size and the horse became more lethargic and showed exercise intolerance. The owner did not wish any further examinations and opted to euthanize the horse. The horse was transported to the Department of Equine Sciences, euthanized, and postmortem examination was performed at the Department of Pathobiology.

Postmortem examination

Multifocal skin lesions were evident macroscopically. Mildly thickened alopecic skin with extensive hyper-

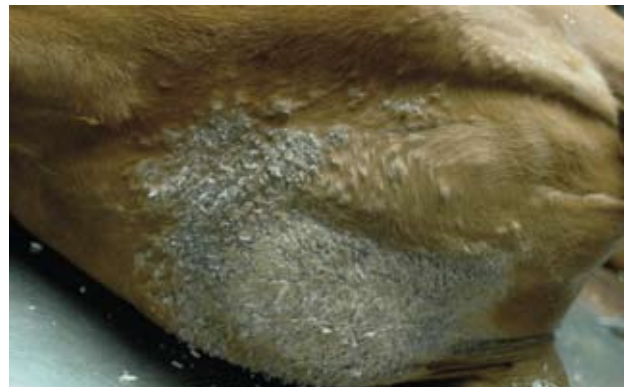
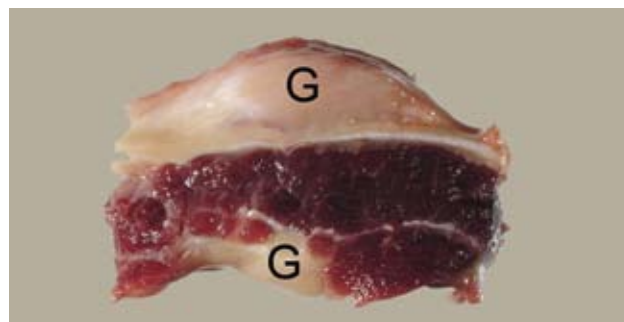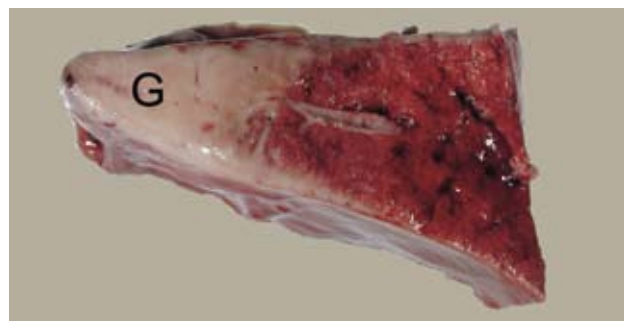


Figure 7. Macroscopic view of the affected skin in the pectoral region of a 7-year-old Dutch Warmblood gelding (case B) at postmortem examination. Note not only the extensive hyperkeratosis and exfoliation of the skin but also the multiple small prominent subcutaneous nodules especially seen surrounding the large greyish hyperkeratotic and scaling patch of skin.

keratosis was localized multifocally on the right pectoral region (figure 7) and less severely on both sides of the head, the left cervical region, and the perineum. Small firm subcutaneous nodules and plaques were found in the right pectoral region, near the crest, on the back, and on the ventral abdominal wall. These nodules and plaques ranged from 2 to 15 cm in diameter. Similar firm multifocal nodular lesions were observed in the left pectoral musculature, and multifocally within the lungs and the diaphragm (figure 8).



8a



8b

Figure 8. Macroscopic photographs of the postmortem findings of a 7-year-old Dutch Warmblood gelding (case B) depicting circumscribed, pale, and firm granulomatous nodules (G) measuring 1 to 3 cm in diameter in the diaphragm (8a), subpleural (top), and within the striated muscle (bottom). Similar extensive but less circumscribed lesions in the pulmonary tissue (8b).

^h Laurierzalf[®], Virbac Nederland BV, Barneveld, The Netherlands.

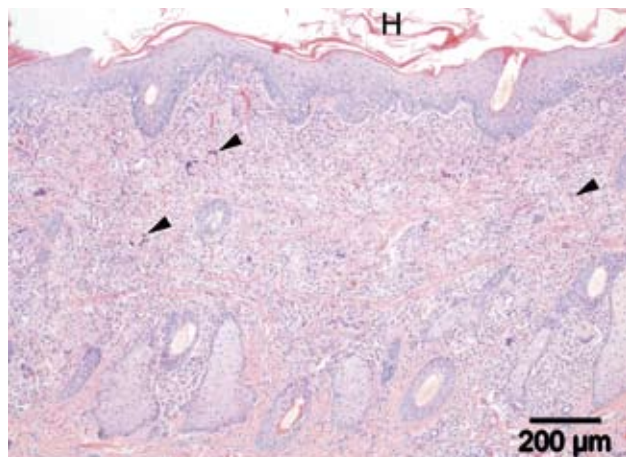
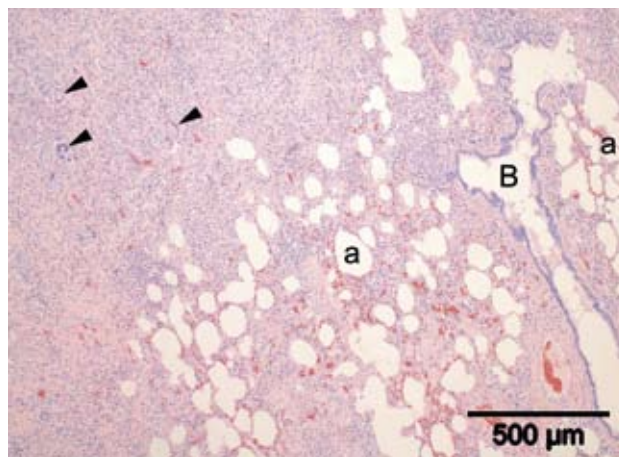


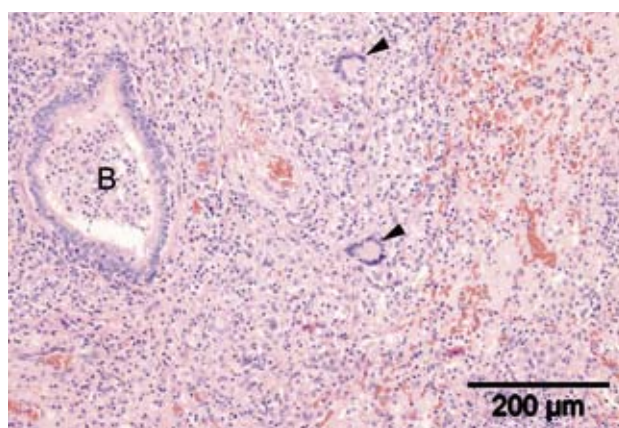
Figure 9. Microscopic examination of the abnormal skin of the pectoral region of a 7-year-old Dutch Warmblood gelding (case B) revealed an extensive inflammatory infiltrate within the superficial dermis of the pectoral region. It is comprised of mainly lymphocytes and histiocytes with regular presence of multinucleated giant cells (arrowheads). Note the thickened hyperplastic epidermis with superficial orthokeratotic hyperkeratosis (H) (haematoxylin-eosin stain).

The lung lesions consisted of two large (measuring approximately 3 x 10 cm) firm pale areas of dorsal subpleural parenchymal consolidation in the left and right main lobes. A third focus of approximately 3 cm in diameter was seen in the left top lung lobe (figure 8b). The cervical, sternal, left axillary, and prescapular lymph nodes were diffusely moderately swollen and firm. On incision, all nodular and plaque-like lesions as well as the affected lymph nodes were circumscribed but non-encapsulated, firm and solid with a pale to greyish discoloration. Other histologically evaluated organs were the pituitary gland, parotid salivary gland, thyroid glands, heart, spleen, pancreas, kidneys, and adrenal glands; these were all unremarkable.

Histological examination of the affected skin revealed similar lesions to those in case A: extensive lymphohistiocytic inflammatory infiltrates admixed with large multinucleated giant cells of the Langhans-type and extensive epidermal hyperkeratosis (figure 9). The firm nodular lesions in the affected tissues and organs contained extensive granulomatous inflammatory infiltrates within a fibrotic matrix. The pulmonary granulomas were markedly fibrotic (figure 10a and 10b). The inflammatory cell population consisted of numerous histiocytes and lymphocytes admixed with lower numbers of plasma cells and neutrophilic granulocytes; multinucleated Langhans giant cells were always present (figures 11, 12 and 13). Comparable small granulomata were present within the liver (figure 14) and occasionally Langhans-type giant cells were seen in the femoral bone marrow. Ziehl-Neelsen stains for acid-fast mycobacteria and periodic acid-Schiff stains for fungi and parasites proved consistently negative. Like case A, these findings were consistent with a diagnosis of generalized sarcoidosis.



10a



10b

Figure 10. Histology of the lung of a 7-year-old Dutch Warmblood gelding (case B) showed large multiple areas of atelectatic pulmonary parenchyma composed of mainly fibrosis and mononuclear inflammatory infiltrates containing multinucleated giant cells (arrowheads). Several inflated and distended alveoli (a) and a bronchiole (B) are also depicted (10a). Higher magnification (10b) shows a neutrophilic exudate within a bronchiole (B) and two Langhans giant cells (arrowheads) in a fibrotic and consolidated area of lung tissue (haematoxylin-eosin stain).

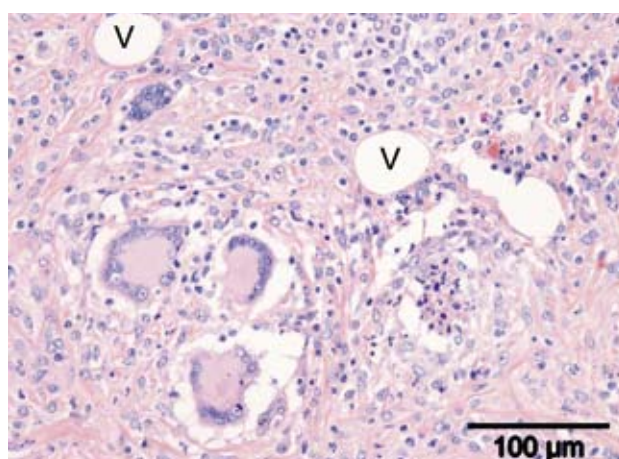


Figure 11. This figure shows a higher magnification of a nodular granulomatous panniculitis of the pectoral region where three large Langhans giant cells (bottom left) are surrounded by histiocytes, lymphocytes and plasma cells. Also notice the increased fibrosis of the subcutis and the presence of several large spherical optically empty adipocytes (V) (haematoxylin-eosin stain).

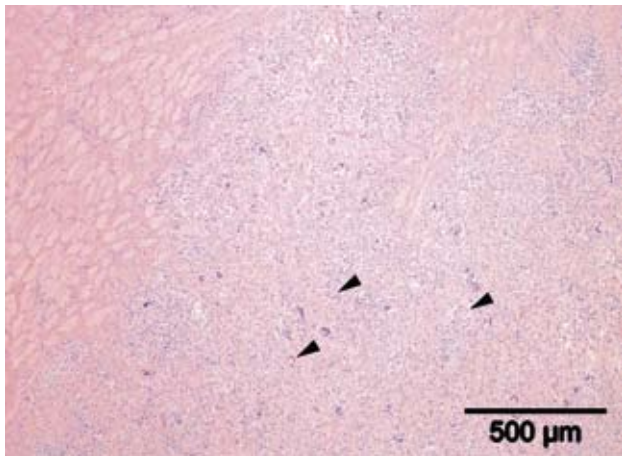


Figure 12. Histology of the nodules in the pectoral striated muscle revealed large moderately circumscribed granulomatous inflammatory lesions also containing numerous multinucleated giant cells (arrowheads). On the top left normal striated muscle is present (haematoxylin-eosin stain).

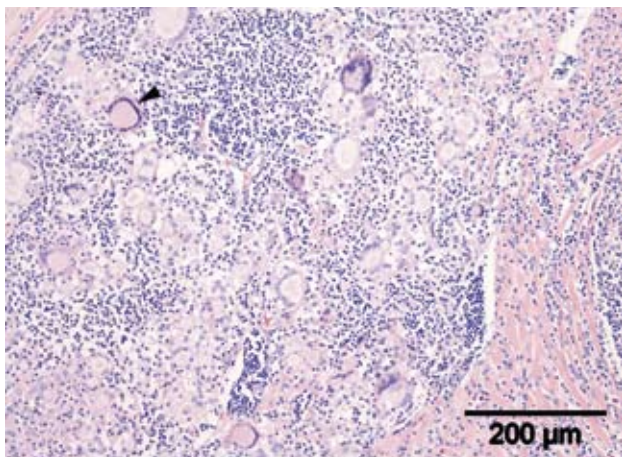


Figure 13. A micrograph of an enlarged and affected sternal lymphnode contains, amongst numerous multinucleated giant cells, an archetypal large Langhans type giant cell with abundant finely granular eosinophilic cytoplasm and margined nuclei in a horse-shoe-shape configuration (arrowhead) (haematoxylin-eosin stain).

DISCUSSION

In human medicine, sarcoidosis is an idiopathic granulomatous disease that usually affects the lung, with dermatological problems occurring later or not at all in the course of the disease (6). In horses, most cases start clinically with dermatological problems (5, 7, 13, 14, 16). The nodular form is quite rare (17, 13). In the cases presented here, the disease started with skin problems in one horse (case A) and with nodules in the other (case B). The pathogenesis of the disease is still unknown both in humans and in horses and is thought to be 'immune-mediated' (6, 13). In both cases presented here, bacterial, fungal, and yeast involvement was not found in skin samples or in tissues at postmortem examination. The owners of both horses mentioned an event that occurred before the onset of clinical problems: colic surgery 6 months previously in case A and vaccination 3 weeks previously in case B. These events are not mentioned as risk factors in the literature, although Spiegel et al. (16)

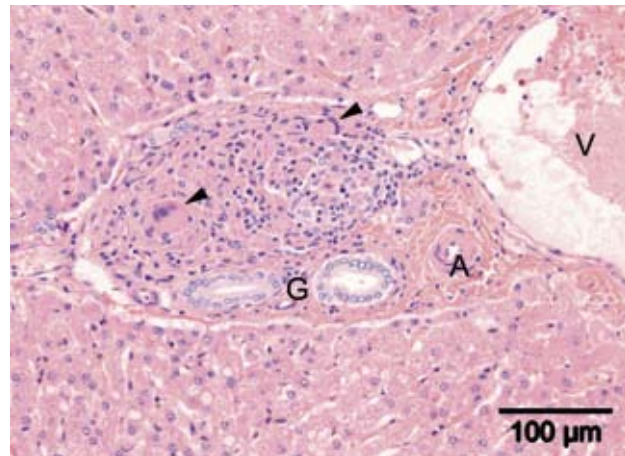


Figure 14. Small granulomata were also present in the liver containing few multinucleated giant cells (arrowheads), in this micrograph affecting a hepatic portal area characterised by bile ducts (G), a small hepatic artery (A) and a large hepatic vein (V) (haematoxylin-eosin stain).

mentioned castration as a possible risk factor because they found a higher incidence of sarcoidosis in geldings.

In humans, the diagnosis of sarcoidosis is based on history, clinical appearance, and histopathology of a skin biopsy (if possible), thereby excluding all other granulomatous diseases of known cause (6). In horses, the most typical clinical signs are alopecia, crusting, and scaling, and the diagnosis is based on this rather typical clinical appearance and a confirmatory skin biopsy (1, 5, 7, 10, 13, 14, 15, 16). Pruritus has been described in cutaneous sarcoidosis in humans (4) and in some cases in horses (7, 16) but not in others (1, 5, 7, 10 and 14). The two horses presented here showed no signs of pruritus.

In humans, pulmonary sarcoidosis is the most common form and thoracic radiography findings are abnormal in more than 90% of affected individuals (6), although predictions for individual patients based on chest radiograph alone are unreliable (6). In horses, thoracic radiographs may be helpful in incidental cases with respiratory signs. The two cases presented here had few respiratory signs. Moreover, given the pathological outcome, thoracic abnormalities would have been detected on radiography in case B only.

Although the literature mentions weight loss as a clinical sign of generalized sarcoidosis, both cases presented here had a normal body condition. However, both horses were euthanized relatively early in the course of the disease because of the poor prognosis. In case B typical granulomatous inflammatory lesions containing multinucleated Langhans type giant cells were also found in the diaphragm and the bone marrow. To our knowledge, this has not been described in horses before, although Spiegel et al. (16) mentioned vertebral and femoral involvement via radiographs showing lesions of the bone in two horses.

In equine sarcoidosis blood haematology and biochemistry findings as neutrophilia, hyperglobulinaemia, mild non-regenerative anaemia, and abnormal kidney and liver function have been described in equine sarcoidosis (16). However, only case B had anaemia and hyperglobulinae-

mia. Again, these findings might have changed had the horses lived longer. Although fine-needle aspiration biopsy is a minimally invasive technique, punch biopsy of the skin and/or a tissue biopsy of a subdermal nodule with a 'liver biopsy needle' are needed to give a reliable ante-mortem diagnosis.

The prognosis of human sarcoidosis is variable and is strongly related to the presenting signs (6). In horses, Spiegel et al. (16) mentioned a more favourable prognosis than other authors (13, 11). The prognosis for localized equine sarcoidosis is good for life, but guarded for the affected skin (15). In humans, treatment for sarcoidosis is not always indicated because the disease may spontaneously resolve and the prolonged use of corticosteroids has severe side-effects (6). However, corticosteroid therapy is indicated in life-threatening disease, if there is cardiac, neurological, or eye involvement, and should also be considered if the disease is progressive (6). Although some equine cases may stay unaltered without any treatment, treatment of both generalized and localized sarcoidosis is limited to prolonged (month to years) systemic corticosteroids (13, 15, 16).

In conclusion, equine generalized sarcoidosis is a rare disease with varying clinical syndromes. In the two cases discussed here, one horse first had dermatological problems (severe crusting) and the other horse initially showed subdermal nodules with a completely normal macroscopic appearance of the overlying skin. Generalized equine sarcoidosis has a poor prognosis, in contrast to localized equine sarcoidosis, which has a favourable prognosis for life and a guarded prognosis for the localized skin problem.

ACKNOWLEDGEMENTS

The authors thank dr. Pieter Jacobs (Equine Practice West Brabant) and dr. Hans Coster (Equine Practice Zwaanshoek) for referring the patients to the Equine Clinic of the Department of Equine Sciences and their contributions to the manuscript. They also are grateful to dr. Lidwien Verdegaal (at that time Department of Equine Sciences, now Bait al Arab Equine Hospital, Kuwait City) and

dr. Roel van Nieuwstadt (Department of Equine Sciences) for clinical help and advice.

REFERENCES

1. Axon JE, Robinson P and Lucas J. Generalised granulomatous disease in a horse. *Aust Vet J* 2004; 82: 48-51.
2. English JC, Patel PJ and Greer KE. Sarcoidosis. *J Am Acad Dermatol* 2001; 44: 725-743.
3. Fadok VA. An overview of equine dermatoses characterized by scaling and crusting. *Vet Clin N Am-Equine* 1995; 11: 43-51.
4. Goldberg A, Lang A and Mekori YA. Prolonged generalized pruritus associated with selective elevation of IgA as the presenting symptoms of sarcoidosis. *Ann Allergy Asthma Immunol* 1995; 74: 387-389.
5. Heath SE, Bell RJ, Clark EG et al. Idiopathic granulomatous disease involving the skin in a horse. *J Am Vet Med Assoc* 1990; 197: 1033-1036.
6. Judson MA. Sarcoidosis: clinical presentation, diagnosis and approach to treatment. *Am J Med Sci* 2008; 335: 26-33.
7. Loewenstein C, Bettenay SV and Mueller RS. A retrospective study of equine sarcoidosis. *Vet Derm* 2004; 15: 67.
8. Newman LS, Rose CS and Maier LA. Sarcoidosis. *N Engl J Med* 1997; 336: 1224-1234.
9. Pascoe RRR and Knottenbelt DC. Sarcoidosis. Immune mediated/allergic diseases. In: *Manual of Equine Dermatology*. London: Harcourt Brace, 1999: 169-170.
10. Rose JF, Littlewood JD, Smith K et al. A series of four cases of generalized granulomatous disease in the horse. In: *proceedings of 3rd World Congress of Veterinary Dermatology* 1998: 562-563.
11. Schlipf JW. Dermatological conditions associated with crusts and scales: Sarcoidosis. In: Robinson NE ed. *Current therapy in Equine Medicine*, 4th edn. Philadelphia: W.B. Saunders, 1997: 384.
12. Scott DW. *Large Animal Dermatology*. Philadelphia: W.B. Saunders, 1988: 326-328.
13. Scott DW and Miller WH. Sarcoidosis. In: *Equine dermatology*. Saunders, St. Louis, 2nd edition, 2003: 675-680.
14. Sellers RS, Toribio RE and Blomme EAG. Idiopathic systemic granulomatous disease and macrophage expression of PTHrP in a miniature pony. *J Comp Pathol* 2001; 125: 214-218.
15. Sloet van Oldruitenborgh-Oosterbaan MM and Koeman JP. Recognition and therapy of sarcoidosis. In: *Proceedings of the 45th BEVA Congress*. Birmingham, 2006: 184-185.
16. Spiegel IB, White SD, Foley JE et al. A retrospective study of cutaneous equine sarcoidosis and its potential infectious aetiological agents. *Vet Dermatol* 2006; 17: 51-62.
17. Stannard AA. Generalized granulomatous disease. In: Robinson NE ed. *Current therapy in equine medicine*, 2nd edn. Philadelphia: W.B. Saunders, 1987: 645-646.

Artikel ingediend: 4 mei 2008

Artikel geaccepteerd: 20 mei 2008