

Granulomatous Pneumonia, Lymphadenopathy, and Hepatopathy in an Adult Horse with Repeated Injection of BCG

R. van den Boom, E.J.B. Veldhuis Kroeze, W.R. Klein, D.J. Houwers, A.G.M. van der Zanden, and M.M. Sloet van Oldruitenborgh-Oosterbaan

Sarcoids are the most common skin tumors in horses,¹ and various treatments are applied with varying degrees of success and diverse recurrence rates. *Bacillus Calmette-Guérin* (BCG) is a modified *Mycobacterium bovis* strain, developed in Paris at the beginning of the 20th century and used as an immunotherapeutic agent since the Second World War. Intralesional application of BCG has been used to treat equine sarcoids since the 1970s^{2,3} and success rates vary from 59 to 100%.¹ The best results are obtained when treating periocular sarcoids and the worst when limbs and axillary region are affected.^{4–6} Large lesions also have a less successful outcome than smaller ones.^{5,6} Both local and systemic reactions have been described after the intralesional injection of BCG.

BCG is used in human medicine as an immunotherapeutic and one of the complications reported is “BCGitis”: a severe systemic disease characterized by bronchopulmonary lesions and a granulomatous hepatitis.^{7–9} This complication can occur soon after BCG administration⁹ but can be delayed for up to several years.^{10,11} All reports involve individuals being treated for urinary bladder cancer by intravesical instillation of BCG.^{7,8,10–12} Treatment of BCGitis involves administration of rifampin and isoniazid combined with prednisolone, and is usually successful.^{7,8,11}

This report describes an adult horse that developed severe interstitial pneumonia, pleuritis, granulomatous lymphadenopathy, and hepatopathy bearing many similarities to BCGitis as described in humans after the administration of a live BCG vaccine for the treatment of equine sarcoids.

Case Report

A 16-year-old gelding was presented to the Department of Equine Sciences at Utrecht University with a skin problem that had started 6 years previously as a

small “wart,” which was removed by the local veterinarian (but not submitted for histology). The lesion recurred but remained small for the next 5 years. The lesion then increased in size to approximately 15 × 15 cm over 1 year, and a large area with wart-like lesions gradually developed on the left shoulder. Both areas had alopecia and scaling, but were not pruritic. The lesions had been treated with various topical antifungal medications without resolution or reduction in size.

At the time of presentation, the horse was in good physical condition and clinical examination revealed no abnormalities, with a respiratory rate of 12 breaths/min, heart rate of 36 beats/min, and rectal temperature of 37.9 °C. Histopathological examination of a biopsy taken from the pectoral region revealed a neoplastic mesenchymal proliferation of pale fibroblasts exhibiting mild pleiomorphism associated with epidermal hyperplasia and hyperkeratosis. These changes are consistent with a diagnosis of equine sarcoid. After diagnosis, the horse was treated with intralesional BCG injections of a live, attenuated BCG vaccine^a on 4 occasions with 3-week intervals. Between 2.6 and 3.6 mL was injected on each occasion. After each treatment, the horse had both a local and systemic reaction, as evidenced by swelling of the pectoral region, lethargy, and inappetence. By the time of the 4th treatment, the skin lesions had decreased in size.

A week after the last BCG injection, the horse again developed local swelling at the injected site and fever, and became anorectic. The fever subsided after the administration of nonsteroidal anti-inflammatory drugs (NSAIDs), but the horse remained anorectic. Several days later (10 days after the last BCG treatment), the horse was admitted to the Department of Equine Sciences at Utrecht University because the fever had recurred (40.1 °C). The horse was also coughing and demonstrated mixed dyspnea. The respiratory rate was 32 breaths/min and there was increased abdominal effort. Wheezes and crackles could be heard on thoracic auscultation. The horse had also lost a considerable amount of weight in the preceding weeks.

Blood examination revealed a moderate leukocytosis (17.8 × 10⁹/L; normal = 7.0–10.0 × 10⁹/L) and the total protein concentration was increased to 91 g/L (normal = 60–85 g/L). Treatment was initiated with antibiotics (gentamicin^b, 6.6 mg/kg, IV q24h and procaine penicillin^c G, 20,000 IU/kg daily IM), flunixin^d (1.1 mg/kg, IV q12h), and clenbuterol^e (0.8 µg/kg PO q12h).

Radiography of the thorax revealed multifocal granular pulmonary opacification, indicating interstitial pulmonary disease (Fig 1), and ultrasonography demonstrated a slight irregularity of the lung edges but no fluid was visible in the thorax.

From the Department of Equine Sciences (van den Boom, Klein, Sloet van Oldruitenborgh-Oosterbaan); Department of Pathobiology (Veldhuis Kroeze); Department of Infectious Diseases & Immunology (Houwers), Faculty of Veterinary Medicine, Utrecht University, Utrecht, The Netherlands; and Laboratory for Medical Microbiology and Public Health, Enschede, The Netherlands (van der Zanden).

Corresponding author: R. van den Boom, Department of Equine Sciences, Faculty of Veterinary Medicine, Utrecht University, Yalelaan 114, 3584 CM Utrecht, The Netherlands; e-mail: r.vandenboom@uu.nl.

Submitted November 6, 2007; Revised January 21, 2008; Accepted February 13, 2008.

Copyright © 2008 by the American College of Veterinary Internal Medicine

10.1111/j.1939-1676.2008.0104.x

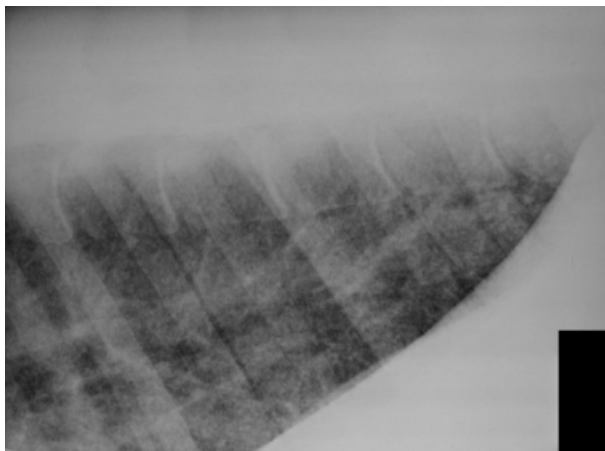


Fig 1. Radiograph of the thorax demonstrating granular pulmonary opacification.

Transtracheal wash was performed on 3 occasions but no pathogenic bacteria were cultured; Ziehl-Neelsen stains were negative and polymerase chain reaction (PCR) failed to demonstrate mycobacterial DNA. Broncho-alveolar lavage was also performed and the percentage of the different cell types was within the reference range, except for an increased number of mast cells (8%, normal <2%).

The signs were considered to be the result of an immune-mediated reaction; treatment was initiated with dexamethasone^f (0.08 mg/kg IV q24h) instead of NSAIDs, and 2 days later antibiotic therapy was stopped. Clinical status improved and the dexamethasone dosage was reduced (to 0.04 mg/kg). Twelve days after admittance the horse was discharged from the clinic, with prednisolone^g (1 mg/kg PO q24h) for 4 weeks. At that time the respiratory rate was 16 breaths/min and the rectal temperature was normal at 37.0 °C.

Nearly 7 weeks later, the horse was readmitted, again with a poor appetite, lethargy, and fever. The respiratory rate was 44 breaths/min, the pattern was abdominal, and wheezes and crackles could again be auscultated on the thorax. Percussion of the thorax did not reveal abnormalities. Radiography still indicated a pattern consistent with interstitial pneumonia, and mature neutrophilia was also present once more ($20.0 \times 10^9/L$). The prognosis was considered to be very poor and euthanasia was advised, but this was declined by the owner.

Treatment was again commenced with corticosteroids (dexamethasone,^f 0.08 mg/kg IV q24h), and ipratropium bromide^h (9 actuations every 6 hours per inhalation) was added to the treatment protocol. This led to some clinical improvement.

After readmission, a lung biopsy was obtained and histological evaluation revealed multiple tubercle-like processes with granulomatous lesions, with central necrosis and calcification. More peripherally, histiocytic epithelioid cells and several multinucleated giant cells (Langhans type) were observed. Ziehl-Neelsen stains were negative, but the histological findings were suggestive of mycobacterial disease and thus tuberculosis could

not be ruled out. Samples were submitted for real-time PCR targeting the *IS6110* element¹³ to determine if DNA from *Mycobacterium tuberculosis* complex was present, with a negative result.

After 2 weeks of dexamethasone treatment, prednisolone administration was commenced, but a day later fever recurred and dexamethasone was again administered. Several days thereafter, the results of histopathology of the lung biopsy became available. Because the horse had been imported from Eastern Europe in its youth, tuberculosis could not be ruled out as a differential diagnosis. Because of the public health concern and the very poor prognosis, given the persistence and recurrence of the signs, the horse was euthanized and necropsied with the owners' consent.

Macroscopically, an extensive multifocal granulomatous pneumonia (Fig 2) associated with severely enlarged tracheobronchial lymph nodes and multifocal small fibrous filaments on the pulmonary pleural surface were seen. On histology, multiple granulomas were present (Fig 3a) in both pulmonary interstitium and lymph nodes. They were characterized by a pale necrotic center surrounded by abundant epithelioid macrophages and several multinucleated Langhans giant cells, and a dense peripheral lymphoplasmacytic infiltrate associated with scant fibrosis (Fig 3b). Ziehl-Neelsen stains of these lesions were again negative. Multifocal to coalescing granulomatous dermatitis and panniculitis were also present at the former BCG injection sites, of which Ziehl-Neelsen stains revealed very faint acid-fast, rod-shaped bacteria in the necrotic centers. In the liver, small granulomas were also present, although these were not as well defined as those in the lungs.

Smears taken from the lungs were also stained for acid-fast bacteria (Ziehl-Neelsen stain), and acid-fast rods were recognized in several smears. Three attempts lasting between 12 weeks and 5 months failed to culture mycobacteria (using both solid and liquid culture media) from affected lung tissues. Spoligotyping, a PCR-based typing

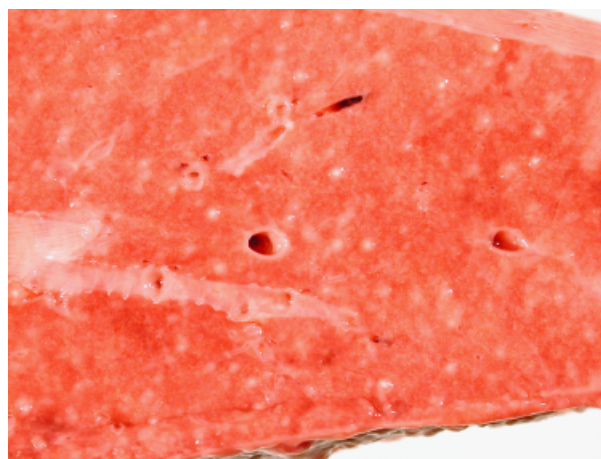

Fig 2. Macroscopic view of the pulmonary cut surface indicating multiple discrete pale granulomatous nodules ranging from approximately 3 to 5 mm in diameter.

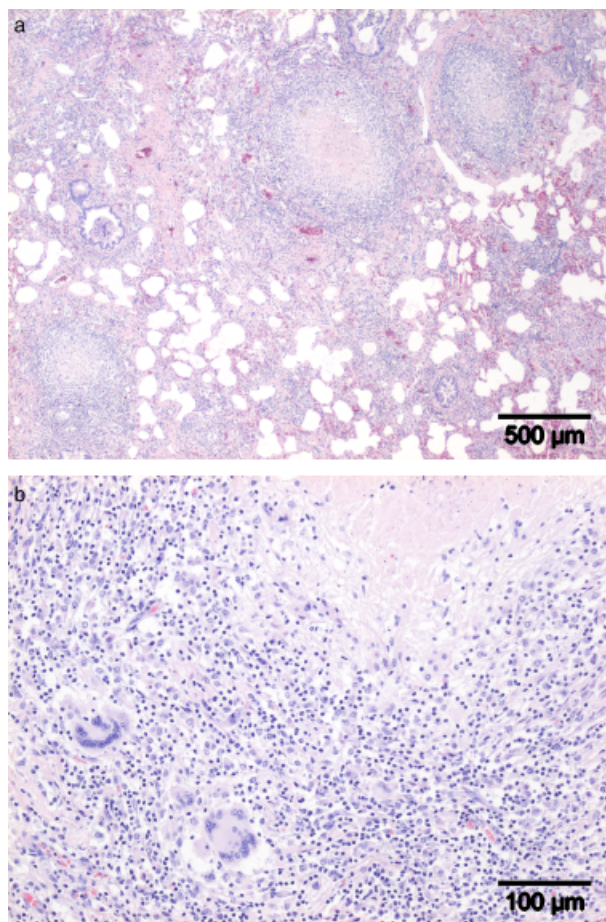


Fig 3. (a) Photomicrograph of a multifocal to coalescing granulomatous pneumonia. The well-circumscribed granulomata are characterized by a pale center, made up of central necrosis surrounded by epithelioid macrophages admixed with multinucleated Langhans giant cells and a peripheral basophilic rim predominantly consisting of lymphocytes and fewer plasmacytes (hematoxylin and eosin [HE] stain). (b) Photomicrograph with a higher magnification of a pulmonary granuloma displaying a pale necrotic area (top right) and 2 multinucleated giant cells of the Langhans-type with a crescent-shaped peripheral cluster of nuclei and abundant eosinophilic granular cytoplasm (near bottom left corner), HE stain.

system for identification and differentiation of *M. tuberculosis* complex strains,¹⁴ and a real-time PCR targeting *IS6110*¹³ were performed on samples from lung tissue. All attempts failed to detect mycobacterial DNA. However, spoligotyping was also performed on material from the Ziehl-Neelsen stained slides (both positive and negative), and here results strongly indicated the presence of members of *M. tuberculosis* complex; but the final identification as *M. bovis* or *M. bovis* BCG remained inconclusive because of incomplete spoligo patterns.¹⁵ The BCG vaccine applied to the horse was cultured and positively identified as *M. bovis* BCG by spoligotyping.

In conclusion, results of spoligotyping strongly suggested the presence of *M. tuberculosis* complex DNA, but the strain could not be identified and repeated attempts to confirm the presence of mycobacteria by culture failed.

BCG is generally considered a safe treatment for equine sarcoids. However, after injection, necrosis, ulceration, and discharge may be seen. Also, some horses demonstrate general malaise, anorexia, pyrexia, lymphadenopathy, and leukocytosis.¹ These changes are transient, but some clinicians advocate pretreatment with flunixin-meglumine combined with corticosteroids. However, this suppresses the immunological response, which is considered to be instrumental to the clinical response. The horse in this report showed more severe clinical and pathological clinical signs after injection than usually observed. More severe reactions are described anecdotally, and there has been some debate regarding the safety of dead and live BCG vaccines, with some discouraging the use of live vaccines. However, there is a lack of scientific evidence to justify this point of view. Moreover, until now, no BCG strain has been found to be far more virulent than others.¹¹ BCG vaccine has been used on more than 1,000 occasions in Utrecht, and the complication described in the present report has not been observed previously.

In human medicine, a severe systemic disease, described as BCGitis, has been reported after treatment with BCG (in patients with bladder cancer).⁷⁻⁹ The condition is reported infrequently¹⁶ and patients suffer from pulmonary lesions and a granulomatous hepatitis. Mycobacteria are not always detected atemortem, and it is considered to be the result of bacterial dissemination rather than a hypersensitivity reaction.¹²

The findings in this horse are similar to those described in human patients suffering BCGitis: granulomatous lesions in lungs and associated lymph nodes and in the liver. The histological findings were consistent with mycobacterial infection. Initially, mycobacteria could not be identified in the lung biopsy or in the lungs (at pathology), but smears taken postmortem revealed acid-fast rods. To confirm a diagnosis of BCGitis, the mycobacteria would need to be cultured and identified as *M. bovis* BCG. However, repeated attempts to culture the agent failed. Alternatively, direct detection of the agent in tissues by molecular techniques could also confirm the diagnosis. *M. tuberculosis* complex DNA was indeed detected in a few specimens by spoligotyping, but further identification to the species level failed for unknown reasons. The horse in this report had been imported from Eastern Europe in its youth, and previous exposure to mycobacteria may have primed the immune system and increased susceptibility to BCG. Notably, the frequency of BCG therapy complications was higher in human patients who suffered from tuberculosis previously than in those who had not.¹⁷ The uncertain history of the horse, from a region in which tuberculosis is more prevalent than in The Netherlands, increased concerns that mycobacteria could be responsible for the clinical signs observed.

Trauma is considered to play a role in dissemination of BCG in human patients. Five patients developed BCGitis after intravesicular BCG treatment, three of which had suffered bleeding at the time of BCG administration.^{7,8} It cannot be excluded that some of the BCG in this horse reached the blood circulation, allowing its

spread to other organs. A delayed reaction to BCG has also been described, and it has been proposed that a reservoir of dormant *M. bovis* may become established after BCG treatment, from which reactivation may occur at a later date, possibly after immuno suppression.¹⁰ In this horse, mycobacteria were indeed identified at the site of BCG injection in the pectoral region and from this site they may have spread.

The findings in the present patient are essentially the same as those described in 7 horses and termed idiopathic granulomatous pneumonia.¹⁸ Those authors point out that the pulmonary lesions seen in their equine patients are very similar to those described in human sarcoidosis, and in recent studies of human sarcoidosis mycobacterial DNA has indeed been detected in lung tissue and blood.^{19,20-22} This provides some evidence to suggest that mycobacteria may play a role in equine granulomatous (lung) disease. Similarly, 4 horses treated with an immunotherapeutic agent based on a mycobacterial cell wall extract¹ also developed multifocal pulmonary granulomas, providing additional support for this theory.²³

The diagnosis of equine idiopathic granulomatous pneumonia depends on histological confirmation and exclusion of known etiological agents.¹⁸ The histological findings in the horse in the present report confirmed granulomatous pneumonia, and it was only when smears from a large surface area of the lung were stained that mycobacteria were found. This provides further evidence for the role of mycobacteria in equine granulomatous lung disease and underlines the difficulty in showing their presence.

Human patients suspected of suffering from BCGitis are treated with a combination of tuberculostatic antibiotic drugs (usually isoniazid and rifampin), and corticosteroids (prednisolone). This combination of drugs was successful in all 5 BCGitis cases reported by Steg et al.⁷ This may explain the transient improvement seen in this horse after treatment with corticosteroids. However, the prognosis of systemic granulomatous disease in horses is considered poor²⁴ and corticosteroids remain the mainstay of therapy, despite a lack of scientific evidence confirming their efficacy. The horse in the present case was euthanized when the results of the lung biopsy (mycobacterial disease) became known, both because of the poor prognosis for the horse itself and because of public health concerns, because tuberculosis could not be ruled out at that time. It was considered unacceptable to expose people and other horses to an animal possibly suffering tuberculosis, and for this reason the horse was not treated with tuberculostatic drugs such as isoniazid and rifampin. It was not until 11 months later that it was proven with certainty that the horse had not suffered from tuberculosis.

^cVentipulmin, Boehringer Ingelheim, Alkmaar, The Netherlands

^fDexadreson, Intervet Nederland BV, Boxmeer, The Netherlands

^gPharmacy of the Faculty of Veterinary Medicine, Utrecht, The Netherlands

^hAtrovent, Boehringer Ingelheim, Alkmaar, The Netherlands

ⁱEquimmune IV, Vetrepharm Research Inc, Athens, GA

Acknowledgments

The authors thank Dr A.J.M. van den Belt for the thoracic radiographs and Dr L.S. Goehring and Dr T. Laan for their contribution to the clinical examination of the horse, in particular for performing the lung biopsy.

References

1. Scott DW, Miller Jr WH. Neoplastic and non-neoplastic tumors. In: Scott DW, Miller Jr WH., eds. Equine Dermatology. St Louis, MO: WB Saunders; 2003:698-795.
2. Murphy JM, Severin GA, Lavach JD, et al. Immunotherapy in ocular equine sarcoid. J Am Vet Med Assoc 1979;174:269-272.
3. Wyman M, Rings MD, Tarr MJ, et al. Immunotherapy in equine sarcoid: A report of two cases. J Am Vet Med Assoc 1977; 171:449-451.
4. Goodrich L, Gerber H, Marti E, et al. Equine sarcoids. Vet Clin North Am Equine Pract 1998;14:607-623, vii.
5. Owen RA, Jagger DW. Clinical observations on the use of BCG cell wall fraction for treatment of periocular and other equine sarcoids. Vet Rec 1987;120:548-552.
6. Klein WR, Bras GE, Misdorp W, et al. Equine sarcoid: BCG immunotherapy compared to cryosurgery in a prospective randomised clinical trial. Cancer Immunol Immunother 1986;21:133-140.
7. Steg A, Leleu C, Debre B, et al. Systemic Bacillus Calmette-Guerin infection, 'BCGitis,' in patients treated by intravesical Bacillus Calmette-Guerin therapy for bladder cancer. Eur Urol 1989;16:161-164.
8. Steg A, Leleu C, Debre B, et al. Systemic Bacillus Calmette-Guerin infection in patients treated by intravesical BCG therapy for superficial bladder cancer. Prog Clin Biol Res 1989;310: 325-334.
9. Proctor DD, Chopra S, Rubenstein SC, et al. Mycobacteremia and granulomatous hepatitis following initial intravesical bacillus Calmette-Guerin instillation for bladder carcinoma. Am J Gastroenterol 1993;88:1112-1115.
10. Izes JK, Bihrlle W III, Thomas CB. Corticosteroid-associated fatal mycobacterial sepsis occurring 3 years after instillation of intravesical bacillus Calmette-Guerin. J Urol 1993;150:1498-1500.
11. Kamphuis JT, Buiting AG, Misere JF, et al. BCG immunotherapy: Be cautious of granulomas. Disseminated BCG infection and mycotic aneurysm as late complications of intravesical BCG instillations. Neth J Med 2001;58:71-75.
12. Leebeek FW, Ouwendijk RJ, Kolk AH, et al. Granulomatous hepatitis caused by Bacillus Calmette-Guerin (BCG) infection after BCG bladder instillation. Gut 1996;38:616-618.
13. Savelkoul PH, Catsburg A, Mulder S, et al. Detection of *Mycobacterium tuberculosis* complex with real time PCR: Comparison of different primer-probe sets based on the IS6110 element. J Microbiol Methods 2006;66:177-180.
14. Kamerbeek J, Schouls L, Kolk A, et al. Simultaneous detection and strain differentiation of *Mycobacterium tuberculosis* for diagnosis and epidemiology. J Clin Microbiol 1997;35:907-914.
15. van der Zanden AG, Te Koppel-Vije EM, Vijaya BN, et al. Use of DNA extracts from Ziehl-Neelsen-stained slides for

Footnotes

^aMedac GmbH, Wedel, Germany

^bGentamicine 5%, Eurovet, Bladel, The Netherlands

^cDepocilline, Mycofarm, De Bilt, The Netherlands

^dBedozane, Eurovet, Bladel, The Netherlands

molecular detection of rifampin resistance and spoligotyping of *Mycobacterium tuberculosis*. J Clin Microbiol 2003;41:1101–1108.

16. Lamm DL, van der Meijden PM, Morales A, et al. Incidence and treatment of complications of bacillus Calmette-Guerin intravesical therapy in superficial bladder cancer. J Urol 1992;147:596–600.

17. Allouc H, Benoit G, Paradis V, et al. Risk of complications during endovesical treatment with BCG for superficial tumor of the bladder. Presse Med 1997;26:1284–1288.

18. Pusterla N, Pesavento PA, Smith P, et al. Idiopathic granulomatous pneumonia in seven horses. Vet Rec 2003;153:653–655.

19. Almenoff PL, Johnson A, Lesser M, et al. Growth of acid-fast L forms from the blood of patients with sarcoidosis. Thorax 1996;51:530–533.

20. Grosser M, Luther T, Muller J, et al. Detection of *M. tuberculosis* DNA in sarcoidosis: Correlation with T-cell response. Lab Invest 1999;79:775–784.

21. Klemen H, Husain AN, Cagle PT, et al. Mycobacterial DNA in recurrent sarcoidosis in the transplanted lung—A PCR-based study on four cases. Virchows Arch 2000;436:365–369.

22. Li N, Bajoghli A, Kubba A, et al. Identification of mycobacterial DNA in cutaneous lesions of sarcoidosis. J Cutan Pathol 1999;26:271–278.

23. Flaminio MJBF. Immunomodulators in respiratory disease treatment. In: Robinson NE., ed. Current Therapy in Equine Medicine. Philadelphia, PA: WB Saunders; 2003:447.

24. Stannard AA. Generalized granulomatous disease. In: Robinson NE., ed. Current Therapy in Equine Medicine. Philadelphia, PA: WB Saunders; 1987:645–646.